



**NCCN Clinical Practice Guidelines in Oncology (NCCN Guidelines®)**

# **Testicular Cancer**

Version 1.2012

**NCCN.org**

**Continue**



National  
Comprehensive  
Cancer  
Network®

# NCCN Guidelines Version 1.2012 Panel Members

## Testicular Cancer

[NCCN Guidelines Index](#)  
[Testicular Cancer TOC](#)  
[Discussion](#)

\* Robert J. Motzer, MD/Chair † ‡  
Memorial Sloan-Kettering Cancer Center

Steven L. Hancock, MD § † ‡  
Stanford Cancer Institute

Roberto Pili, MD †  
Roswell Park Cancer Institute

Neeraj Agarwal, MD ‡  
Huntsman Cancer Institute at the University  
of Utah

Gary R. Hudes, MD † ‡  
Fox Chase Cancer Center

Thomas W. Ratliff, MD †  
St. Jude Children's Research Hospital/University  
of Tennessee Cancer Institute

Clair Beard, MD §  
Dana-Farber/Brigham and Women's Cancer  
Center

Eric Jonasch, MD †  
The University of Texas MD Anderson Cancer  
Center

Bruce G. Redman, DO †  
University of Michigan Comprehensive Cancer  
Center

Sam Bhayani, MD ☉  
Siteman Cancer Center at Barnes-Jewish  
Hospital and Washington University School  
of Medicine

Timothy M. Kuzel, MD ‡  
Robert H. Lurie Comprehensive Cancer Center  
of Northwestern University

Cary N. Robertson, MD ☉  
Duke Cancer Institute

Graeme B. Bolger, MD †  
University of Alabama at Birmingham  
Comprehensive Cancer Center

Clayton Lau, MD ☉  
City of Hope Comprehensive Cancer Center

Charles J. Ryan, MD † ☉  
UCSF Helen Diller Family Comprehensive Cancer  
Center

Mark K. Buyyounouski, MD, MS §  
Fox Chase Cancer Center

Ellis G. Levine, MD †  
Roswell Park Cancer Institute

Joel Sheinfeld, MD ☉  
Memorial Sloan-Kettering Cancer Center

Michael A. Carducci, MD † ‡  
The Sidney Kimmel Comprehensive Cancer  
Center at Johns Hopkins

Daniel W. Lin, MD ☉  
Fred Hutchinson Cancer Research  
Center/Seattle Cancer Care Alliance

Jue Wang, MD †  
UNMC Eppley Cancer Center at  
The Nebraska Medical Center

Sam S. Chang, MD ☉  
Vanderbilt-Ingram Cancer Center

Kim A. Margolin, MD † ‡  
Fred Hutchinson Cancer Research  
Center/Seattle Cancer Care Alliance

\* Richard B. Wilder, MD §  
H. Lee Moffitt Cancer Center & Research Institute

Toni K. Choueiri, MD † ‡  
Dana-Farber/Brigham and Women's Cancer  
Center

M. Dror Michaelson, MD, PhD †  
Massachusetts General Hospital Cancer Center

**NCCN**  
Mary Dwyer, MS  
Rashmi Kumar, PhD

Shilpa Gupta, MD †  
H. Lee Moffitt Cancer Center & Research  
Institute

Thomas Olencki, DO †  
The Ohio State University Comprehensive  
Cancer Center - James Cancer Hospital and  
Solove Research Institute

**Continue**

† Medical oncology  
‡ Hematology/hematology oncology  
§ Radiotherapy/Radiation oncology  
‡ Internal medicine  
☉ Urology  
\* Writing committee member

[NCCN Guidelines Panel Disclosures](#)

**Principles of Radiotherapy for Pure Testicular Seminoma Subcommittee**

**Clair Beard, MD §**  
**Dana-Farber/Brigham and Women's Cancer Center**

**Mark K. Buyyounouski, MD, MS §**  
**Fox Chase Cancer Center**

**Richard B. Wilder, MD §**  
**H. Lee Moffitt Cancer Center & Research Institute**

**Continue**



### [NCCN Testicular Cancer Panel Members](#) [Summary of the Guidelines Updates](#)

#### [Workup, Primary Treatment and Pathologic Diagnosis \(TEST-1\)](#)

#### [Seminoma: Postdiagnostic Workup and Clinical Stage \(TEST-2\)](#)

- [Stage IA, IB \(TEST-3\)](#)
- [Stage IS \(TEST-3\)](#)
- [Stage IIA, IIB \(TEST-4\)](#)
- [Stage IIC, III \(TEST-4\)](#)

#### [Nonseminoma: Postdiagnostic Work-up and Clinical Stage \(TEST-6\)](#)

- [Stage IA, IB, IS \(TEST-7\)](#)
- [Stage IIA, IIB \(TEST-8\)](#)
- [Postchemotherapy Management \(TEST-9\)](#)
- [Postsurgical Management \(TEST-10\)](#)
- [Stage IIC, IIIA, IIIB, IIIC, and Brain Metastases \(TEST-11\)](#)
- [Follow-up for Nonseminoma \(TEST-12\)](#)

#### [Recurrence and Second Line Therapy \(TEST-13\)](#)

#### [Principles of Radiotherapy for Pure Testicular Seminoma \(TEST-A\)](#)

#### [Risk Classification for Advanced Disease \(TEST-B\)](#)

#### [Primary Chemotherapy Regimens for Germ Cell Tumors \(TEST-B\)](#)

#### [Second Line or Subsequent Chemotherapy Regimens for Metastatic Germ Cell Tumors \(TEST-D\)](#)

#### [Principles of Surgery \(TEST-E\)](#)

**Clinical Trials:** The NCCN believes that the best management for any cancer patient is in a clinical trial. Participation in clinical trials is especially encouraged.

To find clinical trials online at NCCN member institutions, [click here: nccn.org/clinical\\_trials/physician.html](#)

**NCCN Categories of Evidence and Consensus:** All recommendations are Category 2A unless otherwise specified.

See [NCCN Categories of Evidence and Consensus](#)

#### [Staging \(ST-1\)](#)

The NCCN Guidelines® are a statement of evidence and consensus of the authors regarding their views of currently accepted approaches to treatment. Any clinician seeking to apply or consult the NCCN Guidelines is expected to use independent medical judgment in the context of individual clinical circumstances to determine any patient's care or treatment. The National Comprehensive Cancer Network® (NCCN®) makes no representations or warranties of any kind regarding their content, use or application and disclaims any responsibility for their application or use in any way. The NCCN Guidelines are copyrighted by National Comprehensive Cancer Network®. All rights reserved. The NCCN Guidelines and the illustrations herein may not be reproduced in any form without the express written permission of NCCN. ©2012.



# NCCN Guidelines Version 1.2012 Updates

## Testicular Cancer

Updates in Version 1.2012 of the NCCN Testicular Cancer Guidelines from Version 2.2011 include:

### New to Guidelines

- Principles of Radiotherapy for Pure Testicular Seminoma ([TEST-A](#)).

### Seminoma

#### TEST-3

- Stage IA, IB and IS

- RT: dose range was removed from the page and added to the new Principles of Radiotherapy.
- Footnote g, “See Discussion for further information on the management of Stage IS” is new to the page.
- Follow-up after surveillance was revised as “H&P, AFP, beta-hCG, LDH: every 3-4 mo for years 1-2, every 6-12 mo for years 3-4, then annually. Abdominal/pelvic CT every 6 mo for years 1-2, every 6-12 mo for year 3, then annually for years 4-5; chest x-ray as clinically indicated for years 1-5” from “H&P, AFP, beta-hCG, LDH: every 3-4 mo for years 1-3, every 6 mo for years 4-7, then annually. Abdominal/pelvic CT at each visit up to 10 years; every 3-4 mo for years 1-3, every 6 mo for years 4-7, then annually chest x-ray as clinically indicated”.
- Follow-up after single dose carboplatin was previously combined with surveillance only and has been added as follows: H&P, AFP, beta-hCG, LDH: every 3 mo for years 1, every 4 mo for year 2, every 6 mo for year 3, then annually. Abdominal/pelvic CT annually for years 1-3; chest x-ray as clinically indicated.
- Follow-up after RT was revised as “H&P + AFP, beta-hCG, LDH: every 4 mo for years 1-2, then annually for years 3-10. Abdominal/pelvic CT annually for 3 years (for patients status post only para-aortic RT); chest x-ray as clinically indicated” from “H&P + AFP, beta-hCG, LDH: every 3-4 mo for year 1, every 6 mo for year 2, then annually. Pelvic CT annually for 3 years (for patients status post only para-aortic RT) chest x-ray as clinically indicated”.

#### TEST-4

- Stage IIA, IIB

- RT dose range was changed from “infradiaphragmatic (30-35 Gy) to include para-aortic and ipsilateral iliac nodes” to “to include para-aortic and ipsilateral iliac lymph nodes to a dose of 30 to 36 Gy”.
- Follow-up after RT was revised as “H&P, AFP, beta-hCG, LDH: every 3 mo for year 1, every 6 months for years 2-5, then annually for years 6-10. Chest x-ray every 6 months for years 1-2. Abdominal CT every 6-12 months for years 1-2, then annually for year 3” from “H&P + chest x-ray, AFP, beta-hCG, LDH: every 3-4 mo for years 1-3, every 6 mo for year 4, then annually. Abdominal CT at month 4 of year 1”.

#### TEST-5

- Footnote j, “If viable seminoma found by retroperitoneal lymph node dissection (RPLND), see TEST-11 (residual embryonal, yolk sac, choriocarcinoma, or seminoma elements)” is new to the page.

[Continued on next page](#)



Updates in Version 1.2012 of the NCCN Testicular Cancer Guidelines from Version 2.2011 include:

### Nonseminoma

#### TEST-7

- Stage IA and IB, surveillance: the qualifier “compliant patients” was removed.
- Stage IB, surveillance was revised as “surveillance for T2 only (category 2B)” from “surveillance (only if T2, compliant patients [category 2B])”.
- The statement “The EP and BEP chemotherapy regimens given at doses and schedules on TEST-C may be considered as category 1 compared with other chemotherapy regimens” was removed from the page. Also for TEST-8 and TEST-10.
- Footnote ‘m’, the category 2B designation was removed from “...and 7-10 days of markers (~~category 2B~~)”. Also for TEST-8, TEST-9, and TEST-11.

#### TEST-9

- For both negative markers, residual mass ( $\geq 1$  cm) and negative markers, no mass or residual mass ( $< 1$  cm), “on CT scan” was added for clarification.

#### TEST-10

- For pN1 and pN2 disease, the qualifiers “compliant” and “noncompliant” were removed.

#### TEST-12

- Table 1 was clarified as “*Follow-up for Stage IA, IB on Surveillance only*” and Table 2 was clarified as “*Follow-up after Complete Response to Chemotherapy and RPLND*” and Table 3 was added for “*Follow-up after RPLND only*”.

#### TEST-13

- Footnote s, “Examples of systems used to estimate prognosis are...” is new to the page.

#### TEST-C

- The statement “Some NCCN Institutions administer bleomycin on a 2, 9, 16 schedule” was removed and the schedule was added to the BEP regimen.

#### TEST-D 2 of 2

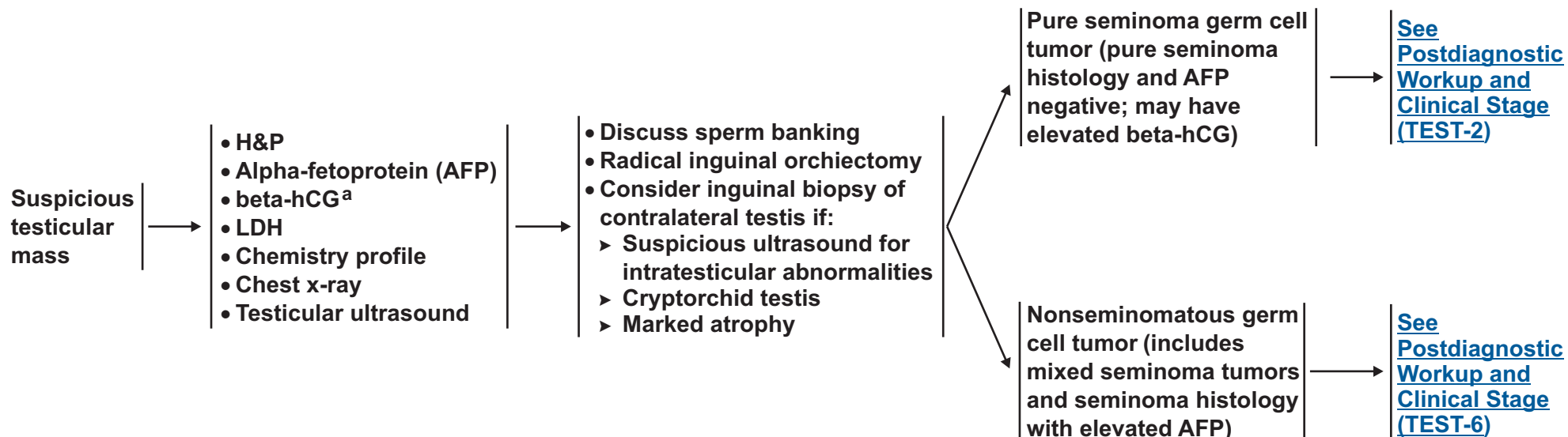
- Palliative chemotherapy regimens were added with a note to “please see references below for dosing”.
  - Gemcitabine/Paclitaxel
  - Gemcitabine/Paclitaxel/Oxaliplatin



### WORKUP

### PRIMARY TREATMENT<sup>b</sup>

### PATHOLOGIC DIAGNOSIS



<sup>a</sup>Quantitative analysis of beta subunit.

<sup>b</sup>Though rare, when a patient presents with rapidly increasing beta-hCG, symptoms related to disseminated disease and a testicular mass, chemotherapy can be initiated immediately without waiting for a biopsy diagnosis.

**Note:** All recommendations are category 2A unless otherwise indicated.  
**Clinical Trials:** NCCN believes that the best management of any cancer patient is in a clinical trial. Participation in clinical trials is especially encouraged.



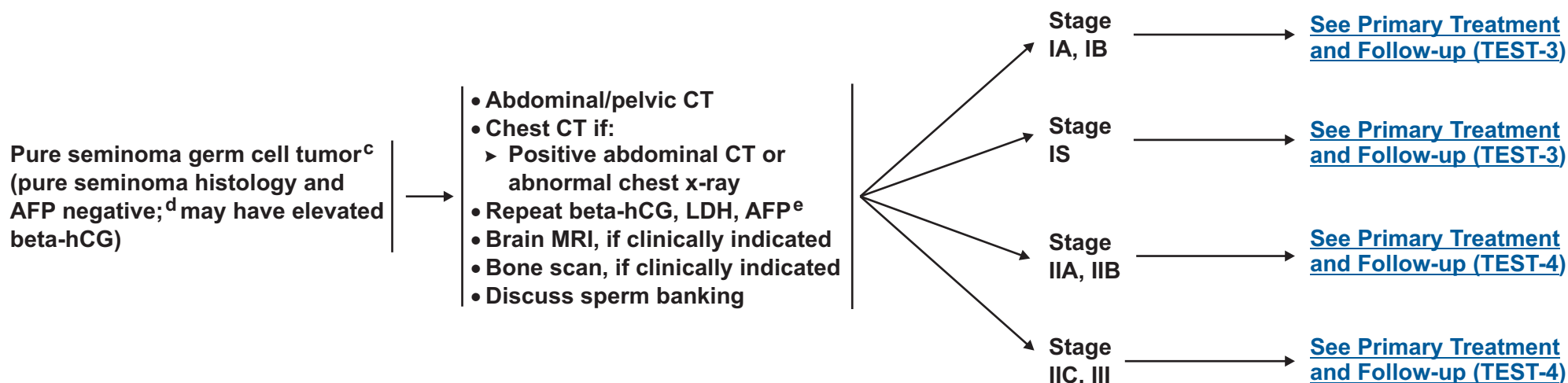
# NCCN Guidelines Version 1.2012

## Testicular Cancer- Pure Seminoma

### PATHOLOGIC DIAGNOSIS

### POSTDIAGNOSTIC WORKUP

### CLINICAL STAGE



<sup>c</sup>Mediastinal primary site seminoma should be treated by risk status used for gonadal seminomas with etoposide/cisplatin for 4 cycles or bleomycin/etoposide/cisplatin for 3 cycles.

<sup>d</sup>If AFP positive, treat as nonseminoma.

<sup>e</sup>Elevated values should be followed after orchiectomy with repeated determination to allow precise staging.

**Note:** All recommendations are category 2A unless otherwise indicated.

**Clinical Trials:** NCCN believes that the best management of any cancer patient is in a clinical trial. Participation in clinical trials is especially encouraged.





# NCCN Guidelines Version 1.2012

## Testicular Cancer - Pure Seminoma

CLINICAL STAGE	PRIMARY TREATMENT	FOLLOW-UP	
Stage IA, IB	Surveillance for pT1 or pT2 tumors (category 1) (preferred)	<ul style="list-style-type: none"> <li>• H&amp;P, AFP, beta-hCG, LDH: every 3-4 mo for years 1-2, every 6-12 mo for years 3-4, then annually</li> <li>• Abdominal/pelvic CT every 6 mo for years 1-2, every 6-12 mo for year 3, then annually for years 4-5; chest x-ray as clinically indicated for years 1-5</li> </ul>	Recurrence, treat according to extent of disease at relapse
	or		
	Single agent carboplatin (category 1) (AUC=7 x 1 cycle or AUC=7 x 2 cycles)		
Stage IS	or	<ul style="list-style-type: none"> <li>• H&amp;P, AFP, beta-hCG, LDH: every 3 mo for years 1, every 4 mo for year 2, every 6 mo for year 3, then annually</li> <li>• Abdominal/pelvic CT annually for years 1-3; chest x-ray as clinically indicated</li> </ul>	Recurrence, treat according to extent of disease at relapse
	RT <sup>f</sup> (category 1)		
	RT <sup>f,g</sup>	<ul style="list-style-type: none"> <li>• H&amp;P + AFP, beta-hCG, LDH: every 4 mo for years 1-2, then annually for years 3-10</li> <li>• Abdominal/pelvic CT annually for 3 years (for patients status post only para-aortic RT); chest x-ray as clinically indicated</li> </ul>	Recurrence, treat according to extent of disease at relapse

<sup>f</sup>See [Principles of Radiotherapy for Treatment of Pure Seminoma \(TEST-A\)](#).

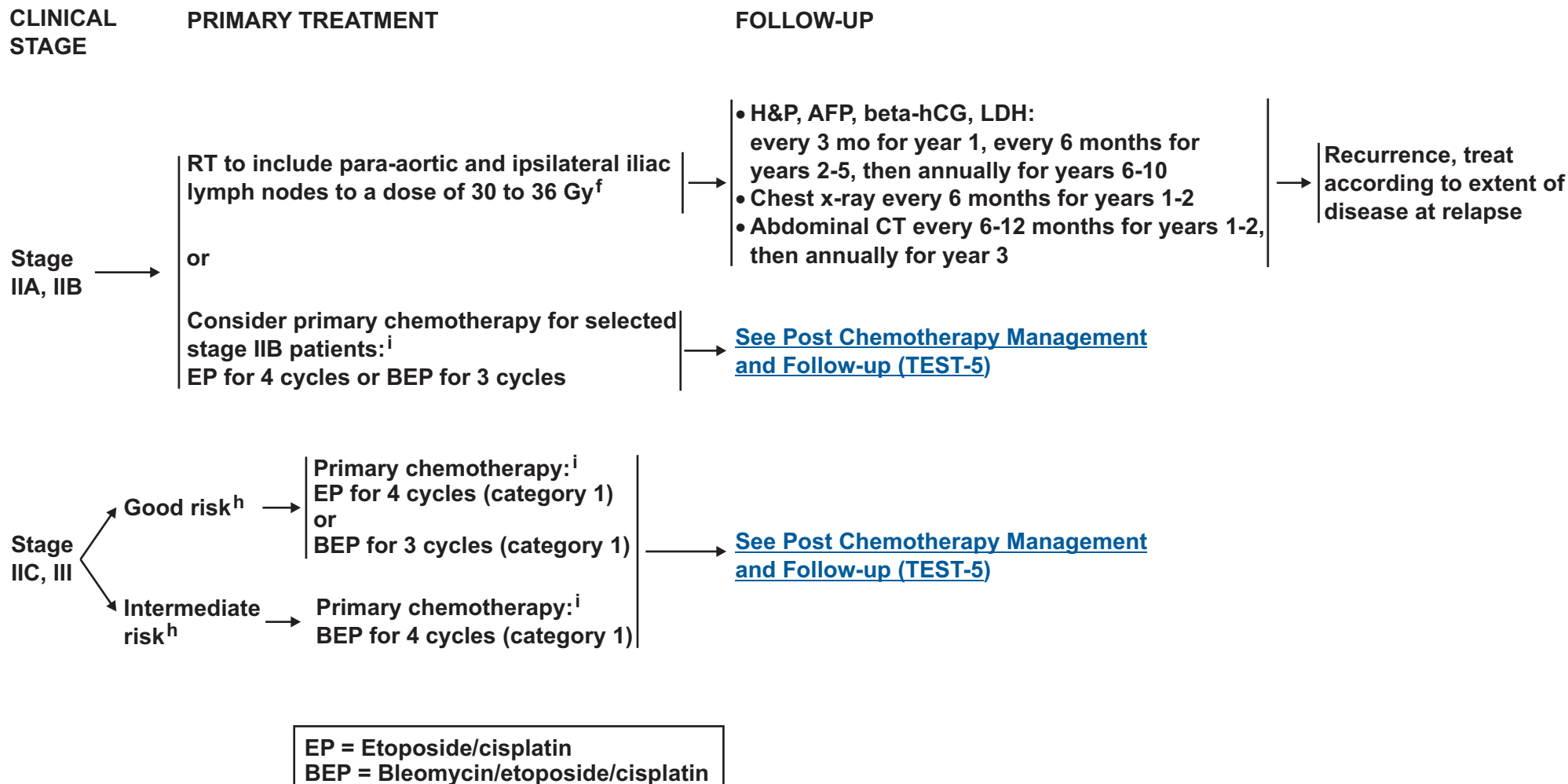
<sup>g</sup>See Discussion for further information on the management of Stage IS.

**Note:** All recommendations are category 2A unless otherwise indicated.  
**Clinical Trials:** NCCN believes that the best management of any cancer patient is in a clinical trial. Participation in clinical trials is especially encouraged.



# NCCN Guidelines Version 1.2012

## Testicular Cancer - Pure Seminoma



<sup>f</sup> See Principles of Radiotherapy for Treatment of Pure Seminoma (TEST-A).

<sup>h</sup> See Risk Classification (TEST-B).

<sup>i</sup> See Primary Chemotherapy Regimens for Germ Cell Tumors (TEST-C).

**Note:** All recommendations are category 2A unless otherwise indicated.

**Clinical Trials:** NCCN believes that the best management of any cancer patient is in a clinical trial. Participation in clinical trials is especially encouraged.



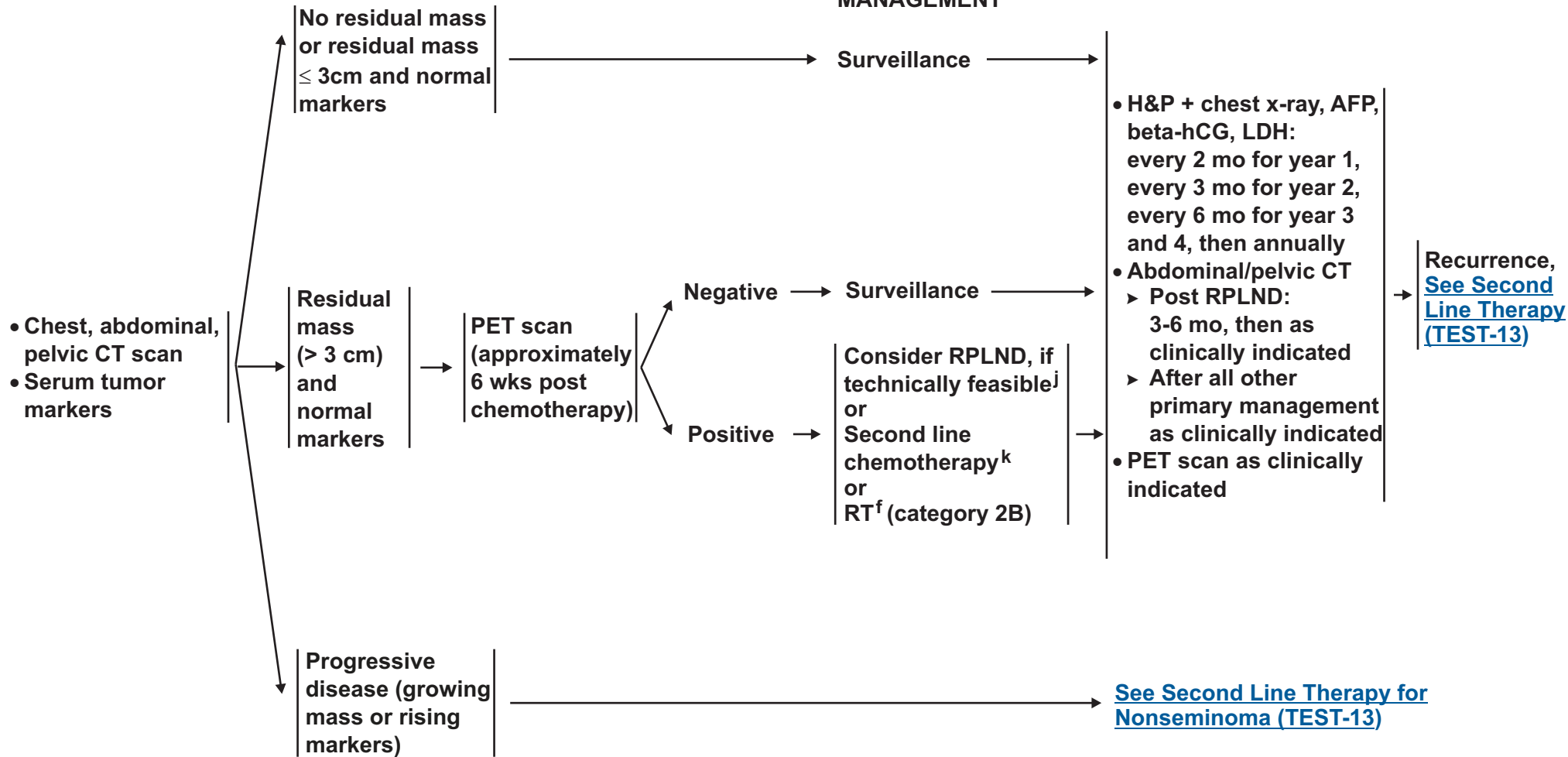
# NCCN Guidelines Version 1.2012

## Testicular Cancer - Pure Seminoma

### STAGE IIB, IIC, III AFTER PRIMARY TREATMENT WITH CHEMOTHERAPY

### POST CHEMOTHERAPY MANAGEMENT

### FOLLOW-UP



<sup>f</sup> See Principles of Radiotherapy for Treatment of Pure Seminoma (TEST-A).

<sup>j</sup> If viable seminoma found by retroperitoneal lymph node dissection (RPLND), see TEST-11 (residual embryonal, yolk sac, choriocarcinoma, or seminoma elements).

<sup>k</sup> See Second Line or Subsequent Chemotherapy Regimens for Metastatic Germ Cell Tumors (TEST-D).

**Note:** All recommendations are category 2A unless otherwise indicated.

**Clinical Trials:** NCCN believes that the best management of any cancer patient is in a clinical trial. Participation in clinical trials is especially encouraged.



### PATHOLOGIC DIAGNOSIS

### POSTDIAGNOSTIC WORKUP<sup>1</sup>

### CLINICAL STAGE

Nonseminomatous germ cell tumor (includes mixed seminoma tumors and seminoma histology with elevated AFP)

- Abdominal/pelvic CT ± chest imaging
- Repeat beta-hCG, LDH, AFP<sup>e</sup>
- Brain MRI, if clinically indicated
- Bone scan, if clinically indicated
- Discuss sperm banking

Stage IA, IB, IS:  
[See Primary Treatment \(TEST-7\)](#)

Stage IIA, IIB:  
[See Primary Treatment \(TEST-8\)](#)

Stage IIC, IIIA, IIIB, IIIC,  
and brain metastasis:  
[See Primary Treatment \(TEST-11\)](#)

<sup>e</sup>Elevated values should be followed after orchiectomy with repeated determination to allow precise staging.

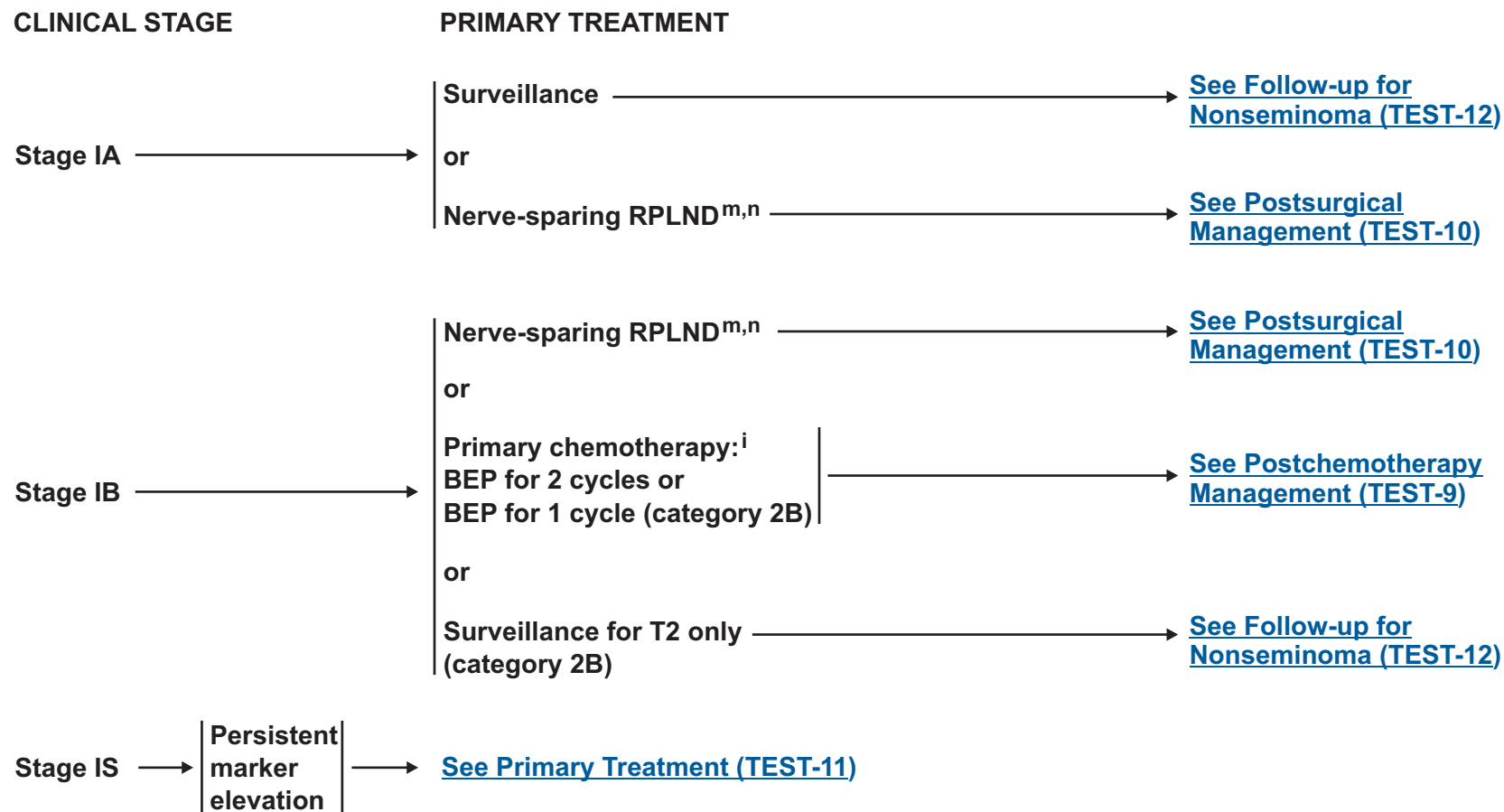
<sup>1</sup>PET scan is not clinically indicated for nonseminoma.

**Note: All recommendations are category 2A unless otherwise indicated.**  
**Clinical Trials: NCCN believes that the best management of any cancer patient is in a clinical trial. Participation in clinical trials is especially encouraged.**



# NCCN Guidelines Version 1.2012

## Testicular Cancer - Nonseminoma



EP = Etoposide/cisplatin  
BEP = Bleomycin/etoposide/cisplatin

<sup>i</sup>[See Primary Chemotherapy Regimens for Germ Cell Tumors \(TEST-C\).](#)

<sup>m</sup>Retroperitoneal lymph node dissection (RPLND) is recommended within 4 weeks of CT scan and 7-10 days of markers.

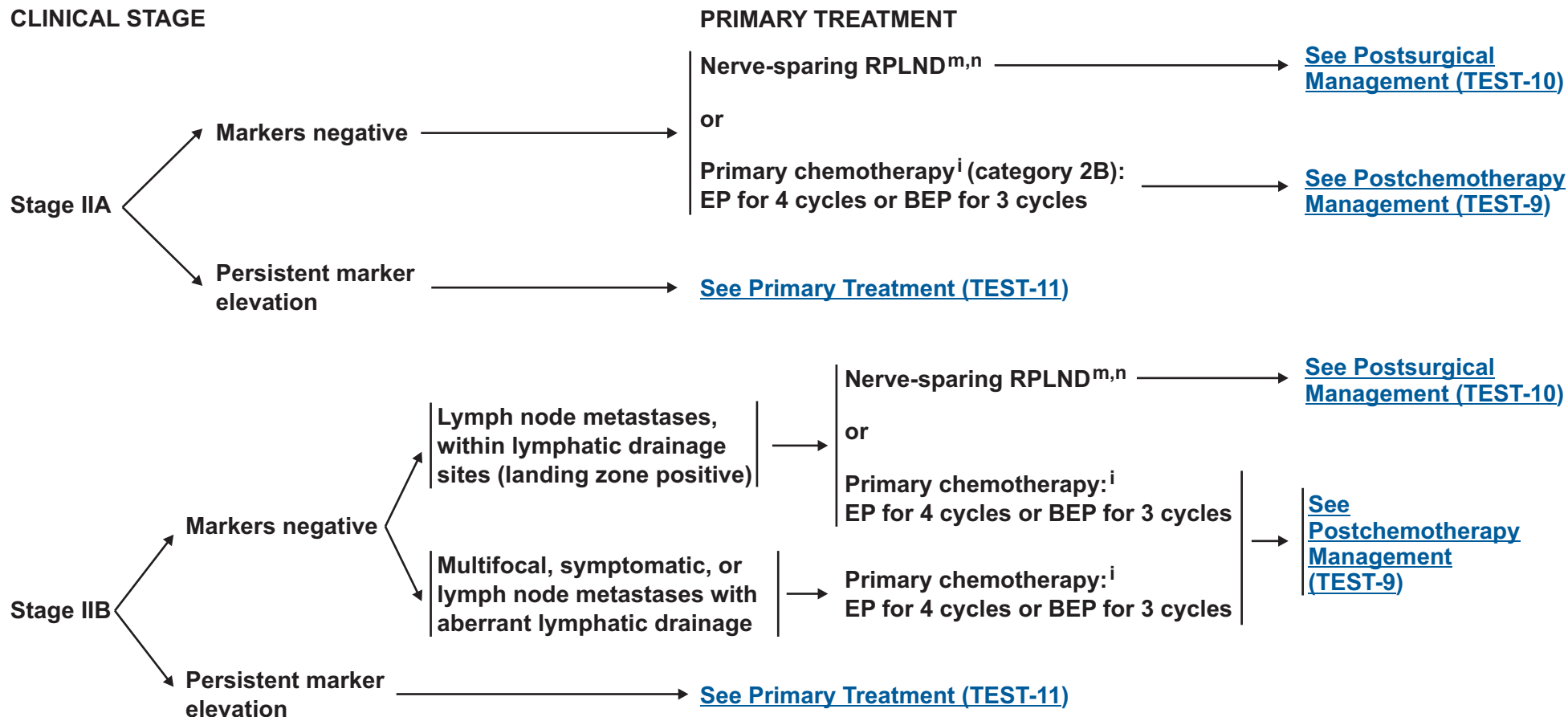
<sup>n</sup>[See Principles of Surgery \(TEST-E\).](#)

**Note:** All recommendations are category 2A unless otherwise indicated.  
**Clinical Trials:** NCCN believes that the best management of any cancer patient is in a clinical trial. Participation in clinical trials is especially encouraged.



# NCCN Guidelines Version 1.2012

## Testicular Cancer - Nonseminoma



EP = Etoposide/cisplatin  
BEP = Bleomycin/etoposide/cisplatin

<sup>i</sup>See [Primary Chemotherapy Regimens for Germ Cell Tumors \(TEST-C\)](#).

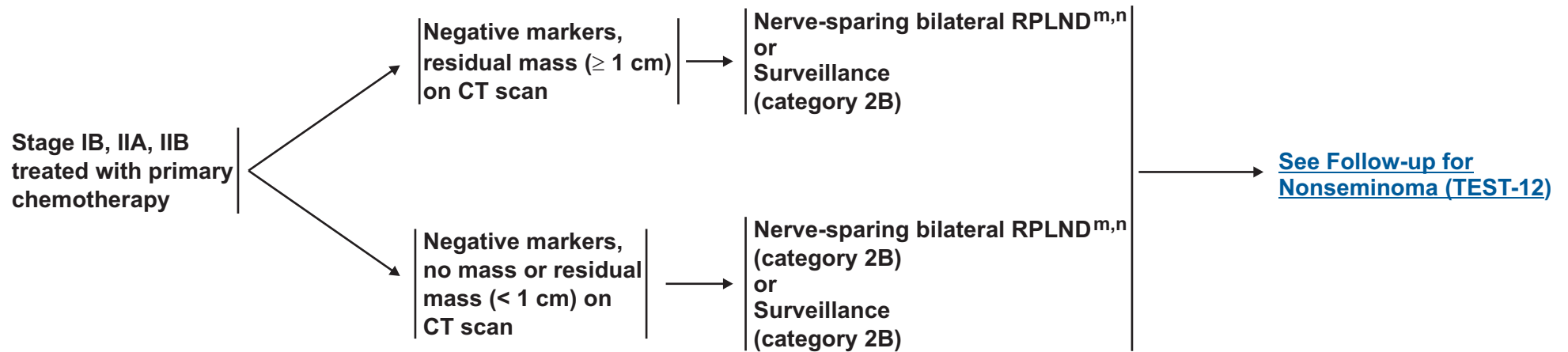
<sup>m</sup>Retroperitoneal lymph node dissection (RPLND) is recommended within 4 weeks of CT scan and 7-10 days of markers.

<sup>n</sup>See [Principles of Surgery \(TEST-E\)](#).

**Note:** All recommendations are category 2A unless otherwise indicated.  
**Clinical Trials:** NCCN believes that the best management of any cancer patient is in a clinical trial. Participation in clinical trials is especially encouraged.



### POSTCHEMOTHERAPY MANAGEMENT



<sup>m</sup>Retroperitoneal lymph node dissection (RPLND) is recommended within 4 weeks of CT scan and 7-10 days of markers.

<sup>n</sup>[See Principles of Surgery \(TEST-E\)](#).

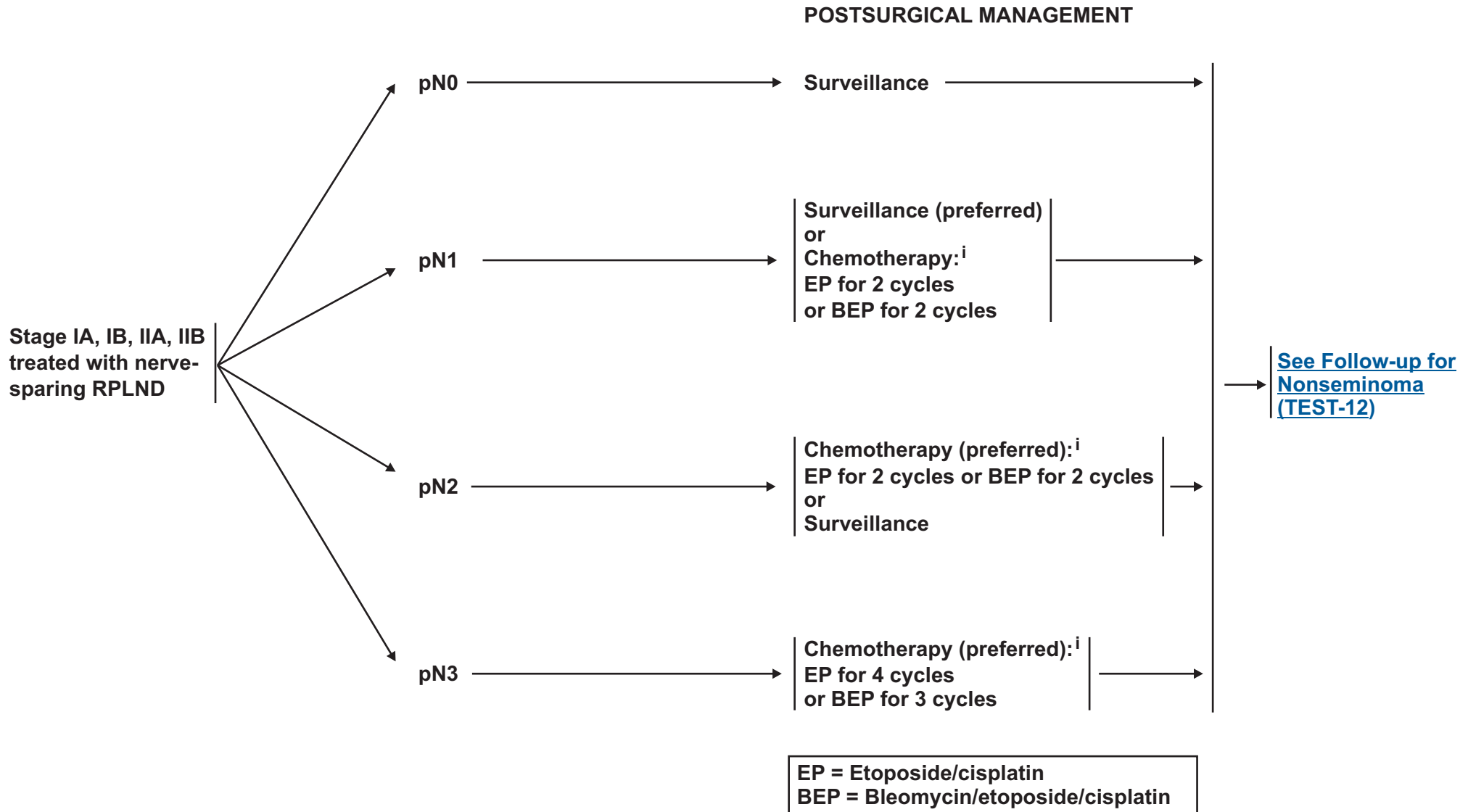
**Note:** All recommendations are category 2A unless otherwise indicated.

**Clinical Trials:** NCCN believes that the best management of any cancer patient is in a clinical trial. Participation in clinical trials is especially encouraged.



# NCCN Guidelines Version 1.2012

## Testicular Cancer - Nonseminoma



<sup>i</sup>[See Primary Chemotherapy Regimens for Germ Cell Tumors \(TEST-C\).](#)

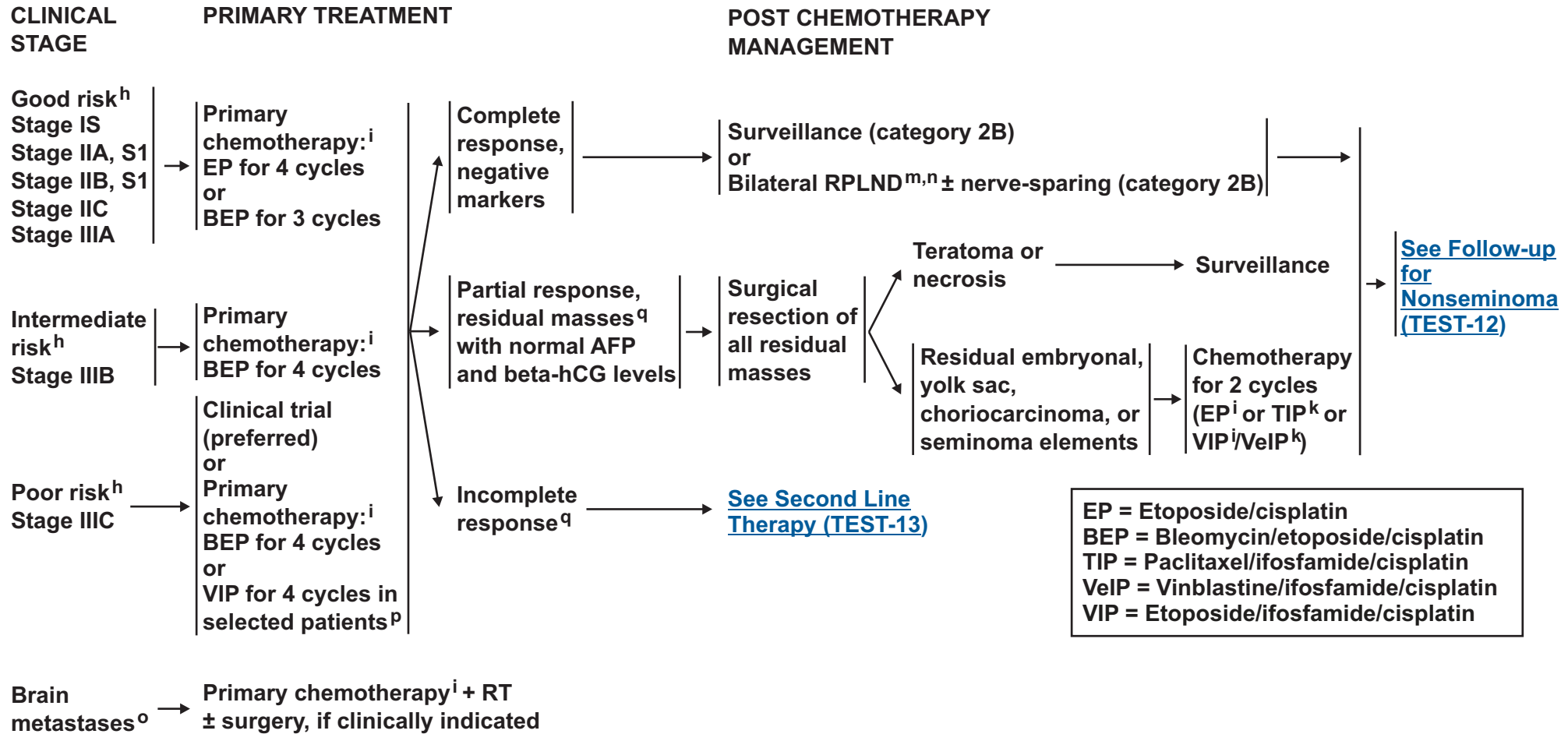
**Note:** All recommendations are category 2A unless otherwise indicated.  
**Clinical Trials:** NCCN believes that the best management of any cancer patient is in a clinical trial. Participation in clinical trials is especially encouraged.





# NCCN Guidelines Version 1.2012

## Testicular Cancer - Nonseminoma



<sup>h</sup>See [Risk Classification \(TEST-B\)](#).

<sup>i</sup>See [Primary Chemotherapy Regimens for Germ Cell Tumors \(TEST-C\)](#).

<sup>k</sup>See [Second Line or Subsequent Chemotherapy Regimens for Metastatic Germ Cell Tumors \(TEST-D\)](#).

<sup>m</sup>Retroperitoneal lymph node dissection (RPLND) is recommended within 4 weeks of CT scan and 7-10 days of markers.

<sup>n</sup>See [Principles of Surgery \(TEST-E\)](#).

<sup>o</sup>Patients should receive adequate treatment for brain metastases, in addition to cisplatin-based chemotherapy.

<sup>p</sup>Patients who may not tolerate bleomycin.

<sup>q</sup>There is limited predictive value for PET scan for residual masses.

**Note:** All recommendations are category 2A unless otherwise indicated.

**Clinical Trials:** NCCN believes that the best management of any cancer patient is in a clinical trial. Participation in clinical trials is especially encouraged.



### FOLLOW-UP FOR NONSEMINOMA

**Table 1** Follow-up for Stage IA, IB on Surveillance *only*

Year	Months between H&P, markers, chest x-ray	Months between abdominal CT
1	1-2	3-4
2	2	4-6
3	3	6-12
4	4	6-12
5	6	12
6+	12	12-24

**Table 2** Follow-up after Complete Response to Chemotherapy and RPLND

Year	Months between H&P, markers, chest x-ray (category 2B for chest x-ray frequency)	Months between abdominal/pelvic CT
1	2-3	6
2	2-3	6-12
3	3-6	12
4	6	12
5	6-12	12
6+	12	As clinically indicated

**Table 3** Follow-up after RPLND *only*

Year	Months between H&P, markers, chest x-ray (category 2B for chest x-ray frequency)	Months between abdominal/pelvic CT
1	2-3	Baseline
2	2-3	As indicated
3	3-6	As indicated
4	6	As indicated
5	6-12	As indicated
6+	12	As indicated

Recurrence, [See Second Line Therapy \(TEST-13\)](#)

**Note:** All recommendations are category 2A unless otherwise indicated.  
**Clinical Trials:** NCCN believes that the best management of any cancer patient is in a clinical trial. Participation in clinical trials is especially encouraged.

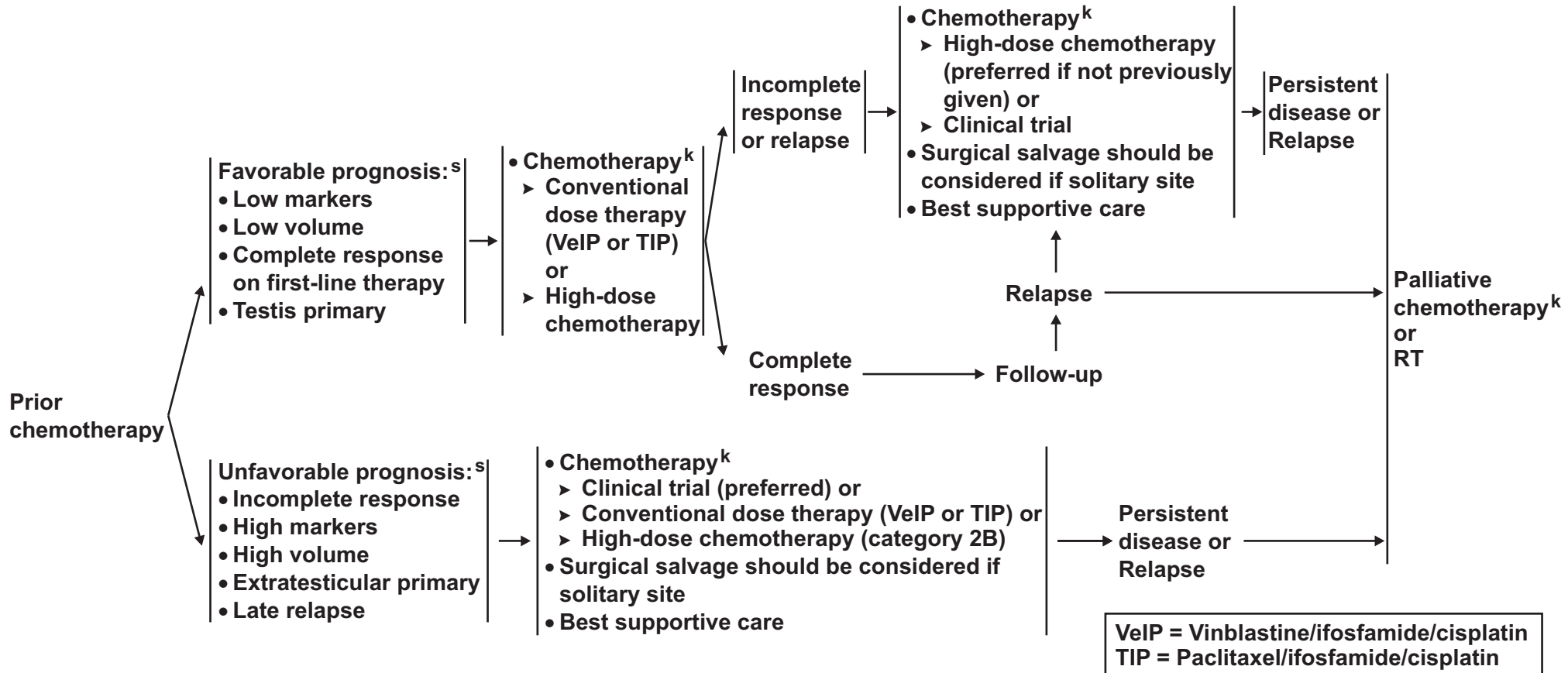


# NCCN Guidelines Version 1.2012

## Testicular Cancer - Nonseminoma

### RECURRENCE<sup>r</sup>

### SECOND LINE THERAPY



No prior chemotherapy → [Treat as per risk status on TEST-11](#)

<sup>k</sup>See [Second Line or Subsequent Chemotherapy Regimens for Germ Cell Tumors \(TEST-D\)](#).

<sup>r</sup>It is preferred that patients with recurrent nonseminoma be treated at centers with expertise in the management of this disease.

<sup>s</sup>Examples of systems used to estimate prognosis are  
 1) Lorch A, Beyer J, Bascoul-Mollevis C, et al. Prognostic factors in patients with metastatic germ cell tumors who experienced treatment failure with cisplatin-based first-line chemotherapy. International Prognostic Factors Study Group. J Clin Oncol 2010;28:4906-4911  
 2) Einhorn LH, Williams SD, Chamness A, et al. High-dose chemotherapy and stem-cell rescue for metastatic germ-cell tumors. New Engl J Med 2007;357:340-348  
 3) Motzer RJ, Geller NL, Tan CC, et al. Salvage chemotherapy for patients with germ cell tumors. The Memorial Sloan-Kettering Cancer Center experience (1979-1989). Cancer 1991;67:1305-1310.

**Note:** All recommendations are category 2A unless otherwise indicated.  
**Clinical Trials:** NCCN believes that the best management of any cancer patient is in a clinical trial. Participation in clinical trials is especially encouraged.



### PRINCIPLES OF RADIOTHERAPY FOR PURE TESTICULAR SEMINOMA

#### General Principles

- Modern radiotherapy involves smaller fields and lower doses than were used in the past. References are provided to support current recommended management.
- Risk-adapted management using tumor size >4 cm and rete testis invasion for Stage I seminoma is discouraged. This is based upon a validation study in 2010, which revealed that tumor size >4 cm and rete testis invasion were not predictors of relapse.<sup>1,2</sup>
- Linear accelerators with >6 MV photons should be used when possible.
- The mean dose (Dmean) and dose delivered to 50% of the volume (D50%) of the kidneys, liver, and bowel are lower with computed tomography (CT)-based anteroposterior-posteroanterior (AP-PA) three-dimensional conformal radiation therapy (3D-CRT) than intensity-modulated radiation therapy (IMRT).<sup>3</sup> As a result, the risk of second cancers arising in the kidneys, liver, or bowel may be lower with 3D-CRT than IMRT, and IMRT is not recommended.<sup>4</sup>
- Timing of Radiotherapy:
  - ▶ Radiotherapy should start within 7 weeks following orchiectomy.
  - ▶ Patients should be treated 5 days per week.
  - ▶ Patients who miss a fraction should be treated to the same total dose and with the same fraction size, extending the overall treatment time slightly.
- Antiemetic medication significantly improves nausea. [See NCCN Antiemesis Guidelines](#). Antiemetic prophylaxis is encouraged at least two hours prior to each treatment, and some cases may require more frequent dosing.

#### Preparation for Radiotherapy

- A discussion of semen analysis and sperm banking prior to orchiectomy is recommended in patients who wish to preserve fertility.<sup>5,6</sup> If sperm banking is desired, it should be performed prior to imaging and the delivery of adjuvant therapy.

#### Treatment Planning Principles

- A non-contrast CT simulation should be performed with the patient supine, arms at his sides, in the treatment position.
  - ▶ Immobilization with a cast may be used to improve the reproducibility of patient setup.
  - ▶ All patients, with the exception of those who have undergone bilateral orchiectomy, should be treated with a scrotal shield. The legs should be separated by a rolled towel of approximately the same diameter as the scrotal shield and its stand.

[For Stage I, see TEST-A 2 of 5](#)

[For Stage IIA, IIB, see TEST-A 3 of 5](#)

[For References, see TEST-A 5 of 5](#)

Note: All recommendations are category 2A unless otherwise indicated.

Clinical Trials: NCCN believes that the best management of any cancer patient is in a clinical trial. Participation in clinical trials is especially encouraged.

**PRINCIPLES OF RADIOTHERAPY FOR PURE TESTICULAR SEMINOMA****Stage I**

- **Dose:** For Stages IA, IB, and IS, a total dose of 20.0 Gy (midplane) in 10 daily 2.0-Gy fractions is recommended for the minority of patients who prefer adjuvant treatment realizing that there is a high likelihood of salvage should a relapse occur during surveillance.<sup>9</sup>
- **Para-aortic (PA)-Strip Fields<sup>10</sup> - Field Arrangement:**
  - ▶ In patients with no history of pelvic or scrotal surgery, para-aortic strip irradiation may be delivered with opposed AP-PA fields. The weights of the fields may be equal.
    - ◊ Recent nodal mapping studies suggest that fields should target the retroperitoneal lymph nodes but not necessarily the ipsilateral renal hilar nodes (see Lateral borders).<sup>11,12</sup>
    - ◊ Superior and inferior borders: Borders may be determined by bony anatomy.
      - The superior border should be placed at the bottom of vertebral body T-11.<sup>13</sup>
      - The inferior border should be placed at the inferior border of vertebral body L-5.<sup>10,14</sup>
    - ◊ Lateral borders:
      - Conventionally, PA-strip fields are approximately 10 cm wide, encompassing the tips of the transverse processes of the para-aortic vertebrae.
      - The location of the kidneys within the PA-strip fields varies from patient to patient.
        - For patients whose kidneys are relatively medial, small renal blocks may be added at the level of T-12. The right and left kidney D50% should be  $\leq 8$  Gy (ie, no more than 50% of each kidney can receive 8 Gy or higher).<sup>3</sup> If only one kidney is present, the kidney D15% should be  $\leq 20$  Gy (ie, no more than 15% of the volume of the kidney can receive 20 Gy or higher).<sup>3</sup>
        - An alternative 3D-CRT planning technique is to base the lateral borders on vascular structures on a treatment planning CT scan without contrast. The aorta and inferior vena cava may be contoured on the CT scan; one should allow a 1.2-1.9-cm margin on the aorta and inferior vena cava to include the para-aortic, paracaval, interaortocaval, and preaortic nodes in the clinical target volume.<sup>11,15</sup> The planning target volume is then established by uniformly expanding the clinical target volume by 0.5 cm in all directions to account for treatment setup errors.<sup>16</sup> A uniform 0.7 cm margin should be provided on the planning target volume to the block edge to take beam penumbra into account (Figure 1, [see TEST-A 4 of 5](#)).<sup>3</sup>

**Special Considerations:**

- Ipsilateral pelvic surgery (eg, inguinal herniorrhaphy or orchiopexy) may alter the lymphatic drainage of the testis. As a result, irradiation of the ipsilateral iliac and inguinal lymph nodes, including the surgical scar from prior surgery, has been advocated even in Stage I patients.<sup>12,17</sup> Given the large volume of tissue that would be irradiated and the resulting increased risks of late effects, other management approaches are recommended for these patients.

[For Stage IIA, IIB, see TEST-A 3 of 5](#)  
[For References, see TEST-A 5 of 5](#)

**Note:** All recommendations are category 2A unless otherwise indicated.

**Clinical Trials:** NCCN believes that the best management of any cancer patient is in a clinical trial. Participation in clinical trials is especially encouraged.



### PRINCIPLES OF RADIOTHERAPY FOR PURE TESTICULAR SEMINOMA

#### Stage IIA-B

- For clinical Stage IIA-B patients, treatment is delivered in two consecutive AP-PA phases (modified dog-leg fields and cone down). There is no break between the 2 phases.
- Modified Dog-leg Fields:
  - ▶ Dose: The initial phase consists of treatment of modified dog-leg fields to 20.0 Gy (midplane) in 10 daily 2.0-Gy fractions<sup>17</sup> or 25.5 Gy in 15 daily 1.7-Gy fractions.<sup>18</sup>
  - ▶ Target: The fields should include the retroperitoneal and proximal ipsilateral iliac lymph nodes.
    - ◊ Modified 'dog-leg' fields as described by Classen et al. are preferred.<sup>19</sup>
      - Care should be taken to ensure coverage of the ipsilateral common, external, and proximal internal iliac lymph nodes down to the top of the acetabulum.
      - The fields can be set up using bony landmarks or by contouring the vascular structures, as for Stage I.
        - The superior border should be placed at the bottom of vertebral body T-11.<sup>20</sup>
        - The inferior border should be placed at the top of the acetabulum.<sup>19</sup>
        - The medial border for the lower aspect of the modified dog-leg fields extends from the tip of the contralateral transverse process of the fifth lumbar vertebra toward the medial border of the ipsilateral obturator foramen.
        - The lateral border for the lower aspect of the modified dog-leg fields is defined by a line from the tip of the ipsilateral transverse process of the fifth lumbar vertebra to the superolateral border of the ipsilateral acetabulum.
        - Preferably, one should contour the aorta and inferior vena cava from the bottom of the T-11 vertebra inferiorly and ipsilateral iliac arteries and veins down to the top of the acetabulum. One should provide a 1.2-1.9-cm margin on these vascular structures for the clinical target volume.<sup>11,15</sup> The planning target volume is then established by uniformly expanding the clinical target volume by 0.5 cm in all directions to account for treatment setup errors.<sup>16</sup> A uniform 0.7 cm margin should be provided on the planning target volume to the block edge to take beam penumbra into account (Figure 2, [see TEST-A 4 of 5](#)).<sup>3</sup>
        - It is not necessary to include the ipsilateral inguinal nodes or the inguinal scar in the AP-PA fields unless the patient has a history of ipsilateral pelvic surgery (e.g., inguinal herniorrhaphy or orchiopexy).<sup>12</sup>
- Cone Down:
  - ▶ Dose: The second phase (cone down) of the radiotherapy consists of daily 2-Gy fractions to a cumulative total dose of approximately 30 Gy for Stage IIA and 36 Gy for Stage IIB.<sup>19</sup>
  - ▶ Target: The nodal mass (gross tumor volume) must be contoured. A uniform, 2-cm margin from the gross tumor volume to block edge should be provided for the AP-PA cone down fields (Figure 3, [see TEST-A 4 of 5](#)).

[For Stage I, see TEST-A 2 of 5](#)  
[For References, see TEST-A 5 of 5](#)

**Note:** All recommendations are category 2A unless otherwise indicated.

**Clinical Trials:** NCCN believes that the best management of any cancer patient is in a clinical trial. Participation in clinical trials is especially encouraged.



### PRINCIPLES OF RADIOTHERAPY FOR PURE TESTICULAR SEMINOMA

Figure 1

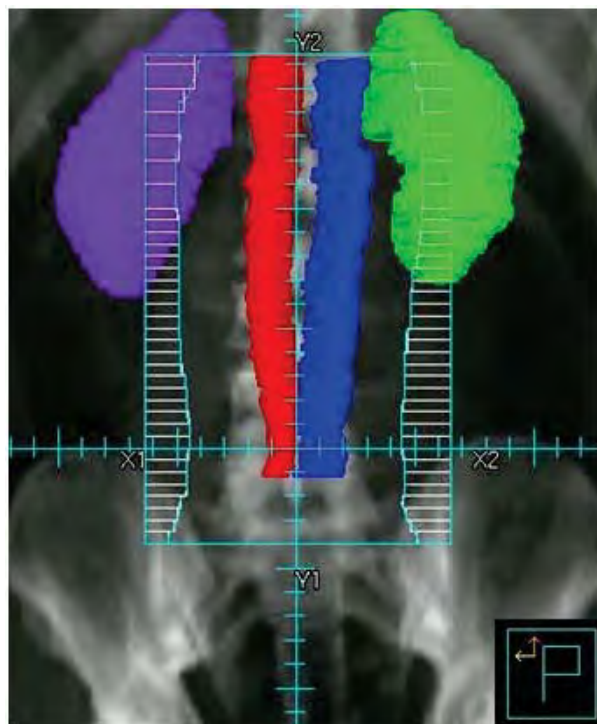

Figure 2

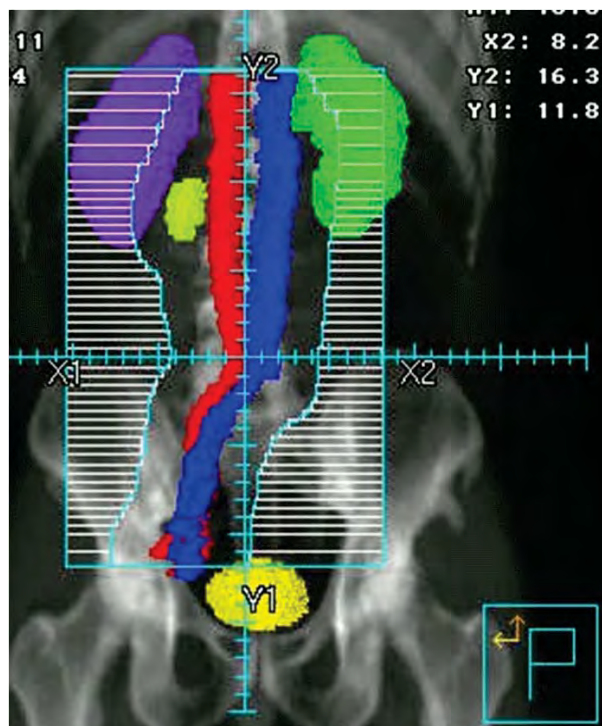
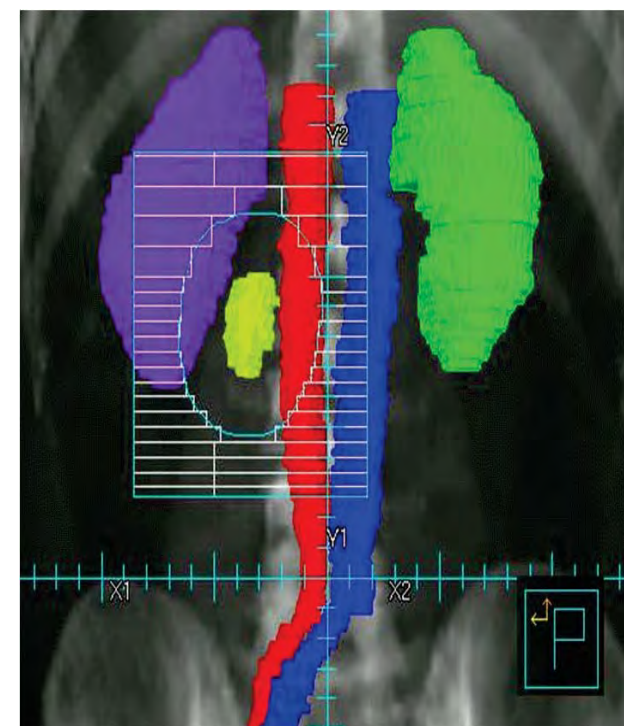


Figure 3



[For Stage I, see TEST-A 2 of 5](#)  
[For Stage IIA, IIB, see TEST-A 3 of 5](#)  
[For References, see TEST-A 5 of 5](#)

**Note:** All recommendations are category 2A unless otherwise indicated.  
**Clinical Trials:** NCCN believes that the best management of any cancer patient is in a clinical trial. Participation in clinical trials is especially encouraged.

**PRINCIPLES OF RADIOTHERAPY FOR PURE TESTICULAR SEMINOMA****References**

1. Chung P, Warde P. Stage I seminoma: adjuvant treatment is effective but is it necessary? *J Natl Cancer Inst* 2011;103:194-196.
2. Chung P: Prognostic factors for relapse in stage I seminoma: A validation study [abstract]. *J Clin Oncol* 2010;28: Abstract 4535.
3. Zilli T, Boudreau C, Doucet R, et al: Bone marrow-sparing intensity-modulated radiation therapy for Stage I seminoma. *Acta Oncol* 2011;50:555-562.
4. Hall EJ, Wuu CS. Radiation-induced second cancers: the impact of 3D-CRT and IMRT. *Int J Radiat Oncol Biol Phys* 2003;56:83-88.
5. Ragni G, Somigliana E, Restelli L, et al. Sperm banking and rate of assisted reproduction treatment: insights from a 15-year cryopreservation program for male cancer patients. *Cancer* 2003;97:1624-1629.
6. Saito K, Suzuki K, Iwasaki A, et al. Sperm cryopreservation before cancer chemotherapy helps in the emotional battle against cancer. *Cancer* 2005;104:521-524.
7. Oliver RT, Mead GM, Rustin GJ, et al. Randomized trial of carboplatin versus radiotherapy for stage I seminoma: mature results on relapse and contralateral testis cancer rates in MRC TE19/EORTC 30982 study (ISRCTN27163214). *J Clin Oncol* 2011;29:957-962.
8. Mead GM, Fossa SD, Oliver RT, et al. Randomized trials in 2466 patients with stage I seminoma: patterns of relapse and follow-up. *J Natl Cancer Inst* 2011;103:241-249.
9. Garmezly B, Pagliaro LC. Choosing treatment for stage I seminoma: who should get what? *Oncology (Williston Park)* 23:753, 759, 2009
10. Fossa SD, Horwich A, Russell JM, et al. Optimal planning target volume for stage I testicular seminoma: A Medical Research Council randomized trial. Medical Research Council Testicular Tumor Working Group. *J Clin Oncol* 1999;17:1146-1154.
11. Dinniwell R, Chan P, Czarnota G, et al. Pelvic lymph node topography for radiotherapy treatment planning from ferumoxtran-10 contrast-enhanced magnetic resonance imaging. *Int J Radiat Oncol Biol Phys* 2009;74:844-851.
12. McMahon CJ, Rofsky NM, Pedrosa I. Lymphatic metastases from pelvic tumors: anatomic classification, characterization, and staging. *Radiology* 2010;254:31-46.
13. Bruns F, Bremer M, Meyer A, et al. Adjuvant radiotherapy in stage I seminoma: is there a role for further reduction of treatment volume? *Acta Oncol* 2005;44:142-148.
14. Classen J, Schmidberger H, Meisner C, et al. Para-aortic irradiation for stage I testicular seminoma: results of a prospective study in 675 patients. A trial of the German testicular cancer study group (GTCSG). *Br J Cancer* 2004;90:2305-2311.
15. Shih HA, Harisinghani M, Zietman AL, et al. Mapping of nodal disease in locally advanced prostate cancer: rethinking the clinical target volume for pelvic nodal irradiation based on vascular rather than bony anatomy. *Int J Radiat Oncol Biol Phys* 2005;63:1262-1269.
16. Boujelbene N, Cosinschi A, Khanfir K, et al. Pure seminoma: a review and update. *Radiat Oncol* 2011;6:90.
17. Jones WG, Fossa SD, Mead GM, et al. Randomized trial of 30 versus 20 Gy in the adjuvant treatment of stage I Testicular Seminoma: a report on Medical Research Council Trial TE18, European Organisation for the Research and Treatment of Cancer Trial 30942 (ISRCTN18525328). *J Clin Oncol* 2005;23:1200-1208.
18. Choo R, Sandler H, Warde P, et al. Survey of radiation oncologists: practice patterns of the management of stage I seminoma of testis in Canada and a selected group in the United States. *Can J Urol* 2002; 9:1479-1485.
19. Classen J, Schmidberger H, Meisner C, et al. Radiotherapy for stages IIA/B testicular seminoma: final report of a prospective multicenter clinical trial. *J Clin Oncol* 2003;21:1101-1106.
20. Paly J, Efstathiou J, Hedgire S, et al. Mapping patterns of nodal metastases in seminoma: Rethinking the para-aortic field [abstract]. *Int J Radiat Oncol Biol Phys* 2011;81:Abstract 88.

**Note: All recommendations are category 2A unless otherwise indicated.**

**Clinical Trials: NCCN believes that the best management of any cancer patient is in a clinical trial. Participation in clinical trials is especially encouraged.**





**RISK CLASSIFICATION FOR ADVANCED DISEASE**  
**(post-orchietomy)<sup>1</sup>**

<b>Risk Status</b>	<b>Nonseminoma</b>	<b>Seminoma</b>
<b>Good Risk</b>	Testicular or retroperitoneal primary tumor and No nonpulmonary visceral metastases and <u>Post-orchietomy markers- all of:</u> AFP < 1,000 ng/mL hCG < 5,000 iu/L LDH < 1.5 x upper limit of normal	Any primary site and No nonpulmonary visceral metastases and Normal AFP Any hCG Any LDH
<b>Intermediate Risk</b>	Testicular or retroperitoneal primary tumor and No nonpulmonary visceral metastases and <u>Post-orchietomy markers- any of:</u> AFP 1,000-10,000 ng/mL hCG 5,000-50,000 iu/L LDH 1.5-10 x upper limit of normal	Any primary site and Nonpulmonary visceral metastases and Normal AFP Any hCG Any LDH
<b>Poor Risk</b>	Mediastinal primary tumor or Nonpulmonary visceral metastases or <u>Post-orchietomy markers- any of:</u> AFP > 10,000 ng/mL hCG > 50,000 iu/L LDH > 10 x upper limit of normal	No patients classified as poor prognosis

Source: Figure 4 from the International Germ Cell Cancer Collaborative Group: International Germ Cell Consensus Classification: A Prognostic Factor-Based Staging System for Metastatic Germ Cell Cancers. J Clin Oncol 1997;15(2):594-603. Reprinted with permission of the American Society of Clinical Oncology.

<sup>1</sup>Markers used for risk classification are post-orchietomy.

**Note: All recommendations are category 2A unless otherwise indicated.**  
**Clinical Trials: NCCN believes that the best management of any cancer patient is in a clinical trial. Participation in clinical trials is especially encouraged.**



### PRIMARY CHEMOTHERAPY REGIMENS FOR GERM CELL TUMORS

#### EP

**Etoposide 100 mg/m<sup>2</sup> IV on Days 1 - 5**  
**Cisplatin 20 mg/m<sup>2</sup> IV on Days 1 - 5**  
**Repeat every 21 days<sup>1</sup>**

#### BEP

**Etoposide 100 mg/m<sup>2</sup> IV on Days 1 - 5**  
**Cisplatin 20 mg/m<sup>2</sup> IV on Days 1 - 5**  
**Bleomycin 30 units IV weekly on Days 1, 8, and 15 or Days 2, 9, 16**  
**Repeat every 21 days<sup>2</sup>**

#### VIP

**Etoposide 75 mg/m<sup>2</sup> IV on Days 1-5**  
**Mesna 120 mg/m<sup>2</sup> slow IV push before ifosfamide on Day 1, then**  
**Mesna 1200 mg/m<sup>2</sup> IV continuous infusion on Days 1-5**  
**Ifosfamide 1200 mg/m<sup>2</sup> on Days 1-5**  
**Cisplatin 20 mg/m<sup>2</sup> IV on Days 1-5**  
**Repeat every 21 days<sup>3</sup>**

<sup>1</sup>Xiao H, Mazumdar M, Bajorin DF, et al. Long-term follow-up of patients with good-risk germ cell tumors treated with etoposide and cisplatin. J Clin Oncol 1997;15:2553-2558.

<sup>2</sup>Saxman SB, Finch D, Gonin R & Einhorn LH. Long-term follow-up of a phase III study of three versus four cycles of bleomycin, etoposide, and cisplatin in favorable-prognosis germ-cell tumors: The Indiana University Experience. J Clin Oncol 1998;16:702-706.

<sup>3</sup>Nichols CR, Catalano PJ, Crawford ED, et al. Randomized comparison of cisplatin and etoposide and either bleomycin or ifosfamide in treatment of advanced disseminated germ cell tumors: An Eastern Cooperative Oncology Group, Southwest Oncology Group, and Cancer and Leukemia Group B Study. J Clin Oncol 1998;16:1287-1293.

**Note: All recommendations are category 2A unless otherwise indicated.**

**Clinical Trials: NCCN believes that the best management of any cancer patient is in a clinical trial. Participation in clinical trials is especially encouraged.**



### SECOND LINE OR SUBSEQUENT CHEMOTHERAPY REGIMENS FOR METASTATIC GERM CELL TUMORS

#### Conventional dose chemotherapy regimens

##### **VeIP**

**Vinblastine 0.11 mg/kg IV Push on Days 1 - 2**  
**Mesna 400 mg/m<sup>2</sup> IV every 8 hours on Days 1 - 5**  
**Ifosfamide 1200 mg/m<sup>2</sup> IV on Days 1 - 5**  
**Cisplatin 20 mg/m<sup>2</sup> IV on Days 1 - 5**  
**Repeat every 21 days<sup>1</sup>**

##### **TIP**

**Paclitaxel 250 mg/m<sup>2</sup> IV on Day 1**  
**Ifosfamide 1500 mg/m<sup>2</sup> IV on Days 2 - 5**  
**Mesna 500 mg/m<sup>2</sup> IV before ifosfamide, and then 4 and 8 hours after each ifosfamide dose on Days 2 - 5**  
**Cisplatin 25 mg/m<sup>2</sup> IV on Days 2 - 5**  
**Repeat every 21 days<sup>2</sup>**

#### High-dose chemotherapy regimens

**Carboplatin 700 mg/m<sup>2</sup> (Body Surface Area) IV**  
**Etoposide 750 mg/m<sup>2</sup> IV**  
**Administer 5, 4, and 3 days before peripheral blood stem cell infusion for 2 cycles<sup>3</sup>**

**Paclitaxel 200 mg/m<sup>2</sup> IV over 24 hours on Day 1**  
**Ifosfamide 2000 mg/m<sup>2</sup> over 4 hours with mesna protection on Days 2 - 4**  
**Repeat every 14 days for 2 cycles followed by**  
**Carboplatin AUC 7 - 8 IV over 60 minutes Days 1 - 3**  
**Etoposide 400 mg/m<sup>2</sup> IV Days 1 - 3**  
**Administer with peripheral blood stem cell support at 14 - 21 day intervals for 3 cycles<sup>4</sup>**

[See Palliative Chemotherapy Regimens \(TEST-D 2 of 2\)](#)

- <sup>1</sup>Loehrer PJ Sr, Lauer R, Roth BJ, et al. Salvage therapy in recurrent germ cell cancer: ifosfamide and cisplatin plus either vinblastine or etoposide. *Ann Intern Med* 1988;109:540-546.
- <sup>2</sup>Kondagunta GV, Bacik J, Donadio A, et al. Combination of paclitaxel, ifosfamide, and cisplatin is an effective second-line therapy for patients with relapsed testicular germ cell tumors. *J Clin Oncol* 2005;23:6549-6555.
- <sup>3</sup>Einhorn LH, Williams SD, Chamness A, et al. High-dose chemotherapy and stem-cell rescue for metastatic germ-cell tumors. *N Engl J Med* 2007;357:340-348.
- <sup>4</sup>Kondagunta GV, Bacik J, Sheinfeld J, et al. Paclitaxel plus ifosfamide followed by high-dose carboplatin plus etoposide in previously treated germ cell tumors. *J Clin Oncol* 2007;25:85-90.

**Note:** All recommendations are category 2A unless otherwise indicated.

**Clinical Trials:** NCCN believes that the best management of any cancer patient is in a clinical trial. Participation in clinical trials is especially encouraged.



**SECOND LINE OR SUBSEQUENT CHEMOTHERAPY REGIMENS FOR  
METASTATIC GERM CELL TUMORS**

**Palliative chemotherapy regimens\***

**Gemcitabine/oxaliplatin**

**Gemcitabine/paclitaxel**

**Gemcitabine/paclitaxel/oxaliplatin**

**\*Please see references below for dosing.**

**GemOx**

Pectasides D, Pectasides M, Farmakis D, et al. Gemcitabine and oxaliplatin (GEMOX) in patients with cisplatin-refractory germ cell tumors: a phase II study. *Ann Oncol* 2004;15:493-497.

Kollmannsberger C, Beyer J, Liersch R, et al. Combination chemotherapy with gemcitabine plus oxaliplatin in patients with intensively pretreated or refractory germ cell cancer: A study of the German Testicular Cancer Study Group. *J Clin Oncol* 2004;22:108-114.

De Giorgi U, Rosti G, Aieta M, et al. Phase II study of oxaliplatin and gemcitabine salvage chemotherapy in patients with cisplatin-refractory nonseminomatous germ cell tumor. *Eur Urol* 2006;50:893-894.

**Paclitaxel/gemcitabine**

Einhorn LH, Brames MJ, Juliar B, Williams SD. Phase II study of paclitaxel plus gemcitabine salvage chemotherapy for germ cell tumors after progression following high-dose chemotherapy with tandem transplant. *J Clin Oncol* 2007;25:513-516.

Mulherin B, Brames M, Einhorn L. Long-term survival with paclitaxel and gemcitabine for germ cell tumors after progression following high-dose chemotherapy with tandem transplants [abstract]. *J Clin Oncol* 2011;29:Abstract 4562.

**Gemcitabine/oxaliplatin/paclitaxel**

Bokemeyer C, Oechsle K, Honecker F, Mayer F, Hartmann JT, Waller CF, Böhlke I, Kollmannsberger C; German Testicular Cancer Study Group. Combination chemotherapy with gemcitabine, oxaliplatin, and paclitaxel in patients with cisplatin-refractory or multiply relapsed germ-cell tumors: A study of the German Testicular Cancer Study Group. *Ann Oncol* 2008;19:448-453.

**Note: All recommendations are category 2A unless otherwise indicated.**

**Clinical Trials: NCCN believes that the best management of any cancer patient is in a clinical trial. Participation in clinical trials is especially encouraged.**



### PRINCIPLES OF SURGERY

- **RPLND is the standard approach to the surgical management of nonseminoma germ cell tumor (NSGCT) in both primary and post-chemotherapy setting.**
- **A template dissection or a nerve-sparing approach to minimize the risk of ejaculatory disorders should be considered in patients undergoing primary RPLND for stage I nonseminoma.**
- **The “split and roll” technique in which lumbar vessels are identified and sequentially ligated allows resection of all lymphatic tissue around and behind the great vessels (aorta, IVC) and minimizes the risk of an in-field recurrence.**

#### Post-chemotherapy setting

- **Referral to high volume centers should be considered for surgical resection of masses post-chemotherapy.**
- **Completeness of resection is an independent and consistent predictive variable of clinical outcome. In post-chemotherapy RPLND, surgical margins should not be compromised in an attempt to preserve ejaculation. Additional procedures and resection of adjacent structures may be required.**
- **Post-chemotherapy RPLND is indicated in metastatic NSGCT patients with a residual retroperitoneal mass following systemic chemotherapy and normalized post-chemotherapy serum tumor markers.**
- **A full bilateral template RPLND should be performed in all patients undergoing RPLND in the post-chemotherapy setting, with the boundaries of dissection being the renal hilar vessels (superiorly), ureters (laterally), and the common iliac arteries (inferiorly).**

**Note:** All recommendations are category 2A unless otherwise indicated.

**Clinical Trials:** NCCN believes that the best management of any cancer patient is in a clinical trial. Participation in clinical trials is especially encouraged.

**Table 1**

### American Joint Committee on Cancer (AJCC) TNM Staging System for Testis Cancer (7th ed., 2010)

#### Primary Tumor (T)\*

The extent of primary tumor is usually classified after radical orchiectomy, and for this reason, a *pathologic* stage is assigned.

pTX	Primary tumor cannot be assessed
pT0	No evidence of primary tumor (e.g. histologic scar in testis)
pTis	Intratubular germ cell neoplasia (carcinoma in situ)
pT1	Tumor limited to the testis and epididymis without vascular/lymphatic invasion; tumor may invade into the tunica albuginea but not the tunica vaginalis
pT2	Tumor limited to the testis and epididymis with vascular/lymphatic invasion, or tumor extending through the tunica albuginea with involvement of the tunica vaginalis
pT3	Tumor invades the spermatic cord with or without vascular/lymphatic invasion
pT4	Tumor invades the scrotum with or without vascular/lymphatic invasion

\*Note: Except for pTis and pT4, extent of primary tumor is classified by radical orchiectomy. TX may be used for other categories in the absence of radical orchiectomy.

Used with the permission of the American Joint Committee on Cancer (AJCC), Chicago, Illinois. The original and primary source for this information is the AJCC Cancer Staging Manual, Seventh Edition (2010) published by Springer Science and Business Media LLC (SBM). (For complete information and data supporting the staging tables, visit [www.springer.com](http://www.springer.com).) Any citation or quotation of this material must be credited to the AJCC as its primary source. The inclusion of this information herein does not authorize any reuse or further distribution without the expressed, written permission of Springer SBM, on behalf of the AJCC.

#### Regional Lymph Nodes (N)

##### Clinical

NX	Regional lymph nodes cannot be assessed
N0	No regional lymph node metastasis
N1	Metastasis with a lymph node mass 2 cm or less in greatest dimension; or multiple lymph nodes, none more than 2 cm in greatest dimension
N2	Metastasis with a lymph node mass, more than 2 cm but not more than 5 cm in greatest dimension; or multiple lymph nodes, any one mass greater than 2 cm but not more than 5 cm in greatest dimension
N3	Metastasis with a lymph node mass more than 5 cm in greatest dimension

##### Pathologic (pN)

pNX	Regional lymph nodes cannot be assessed
pN0	No regional lymph node metastasis
pN1	Metastasis with a lymph node mass 2 cm or less in greatest dimension and less than or equal to five nodes positive, none more than 2 cm in greatest dimension
pN2	Metastasis with a lymph node mass more than 2 cm but not more than 5 cm in greatest dimension; or more than five nodes positive, none more than 5 cm; or evidence of extranodal extension of tumor
pN3	Metastasis with a lymph node mass more than 5 cm in greatest dimension

#### Distant Metastasis (M)

M0	No distant metastasis
M1	Distant metastasis
M1a	Nonregional nodal or pulmonary metastasis
M1b	Distant metastasis other than to nonregional lymph nodes and lung



**Table 1 (continued)**

**American Joint Committee on Cancer (AJCC)  
TNM Staging System for Testis Cancer (7th ed., 2010)**

**ANATOMIC STAGE/PROGNOSTIC GROUPS**

Group	T	N	M	S (Serum Tumor Markers)
Stage 0	pTis	N0	M0	S0
Stage I	pT1-4	N0	M0	SX
Stage IA	pT1	N0	M0	S0
Stage IB	pT2	N0	M0	S0
	PT3	N0	M0	S0
	PT4	N0	M0	S0
Stage IS	Any pT/TX	N0	M0	S1-3
Stage II	Any pT/Tx	N1-3	M0	SX
Stage IIA	Any pT/TX	N1	M0	S0
	Any pT/TX	N1	M0	S1
Stage IIB	Any pT/TX	N2	M0	S0
	Any pT/TX	N2	M0	S1
Stage IIC	Any pT/TX	N3	M0	S0
	Any pT/TX	N3	M0	S1
Stage III	Any pT/TX	Any N	M1	SX
Stage IIIA	Any pT/TX	Any N	M1a	S0
	Any pT/TX	Any N	M1a	S1
Stage IIIB	Any pT/TX	N1-3	M0	S2
	Any pT/TX	Any N	M1a	S2
Stage IIIC	Any pT/TX	N1-3	M0	S3
	Any pT/TX	Any N	M1a	S3
	Any pT/Tx	Any N	M1b	Any S

**Serum Tumor Markers (S)**

SX	Marker studies not available or not performed	
SO	Marker study levels within normal limits	
S1	LDH < 1.5 x N* <i>and</i> hCG (mlu/mL) < 5,000 <i>and</i> AFP (ng/ml) < 1,000	
	S2	LDH 1.5-10 x N <i>or</i> hCG (mlu/mL) 5,000-50,000 <i>or</i> AFP (ng/ml) 1,000-10,000
		S3

\*N indicates the upper limit of normal for the LDH assay.

Used with the permission of the American Joint Committee on Cancer (AJCC), Chicago, Illinois. The original and primary source for this information is the AJCC Cancer Staging Manual, Seventh Edition (2010) published by Springer Science and Business Media LLC (SBM). (For complete information and data supporting the staging tables, visit [www.springer.com](http://www.springer.com).) Any citation or quotation of this material must be credited to the AJCC as its primary source. The inclusion of this information herein does not authorize any reuse or further distribution without the expressed, written permission of Springer SBM, on behalf of the AJCC.



## Discussion

### NCCN Categories of Evidence and Consensus

**Category 1:** Based upon high-level evidence, there is uniform NCCN consensus that the intervention is appropriate.

**Category 2A:** Based upon lower-level evidence, there is uniform NCCN consensus that the intervention is appropriate.

**Category 2B:** Based upon lower-level evidence, there is NCCN consensus that the intervention is appropriate.

**Category 3:** Based upon any level of evidence, there is major NCCN disagreement that the intervention is appropriate.

**All recommendations are category 2A unless otherwise noted.**

### Overview

An estimated 8,590 new cases of testicular cancer will be diagnosed in the United States in 2012.<sup>1</sup> Germ cell tumors (GCTs) comprise 95% of malignant tumors arising in the testes. These tumors also occur occasionally in extragonadal primary sites, but they are still managed the same as testicular GCTs. Although GCTs are relatively uncommon tumors that comprise only 2% of all human malignancies, they constitute the most common solid tumor in men between the ages of 15 and 34 years. In addition, the worldwide incidence of these tumors has more than doubled in the past 40 years.

Several risk factors for GCT development have been identified, including prior history of a GCT, positive family history, cryptorchidism, testicular dysgenesis, and Klinefelter's syndrome. GCTs are classified as seminoma or nonseminoma. Nonseminomatous tumors often

include multiple cell types, including embryonal cell carcinoma, choriocarcinoma, yolk sac tumor, and teratoma. Teratomas are considered to be either mature or immature depending on whether adult-type differential cell types or partial somatic differentiation, similar to that present in the fetus, is found. Rarely, a teratoma histologically resembles a somatic cancer, such as sarcoma or adenocarcinoma, and is then referred to as a teratoma with malignant transformation.

The serum tumor markers alpha-fetoprotein (AFP), lactate dehydrogenase (LDH), and beta-human chorionic gonadotropin (beta-HCG) are critical in diagnosing the GCTs, determining prognosis, and assessing treatment outcome. These should be determined before, during, and after treatment and throughout the follow-up period. Serum tumor markers are very useful for monitoring all stages of nonseminomas. Serum markers are also useful in monitoring metastatic seminomas because elevated marker levels are the early signs of relapse.

LDH is a less specific marker compared to AFP and HCG. AFP is a serum tumor marker produced by nonseminomatous cells (embryonal carcinoma, yolk-sac tumor) and may be seen at any stage. The approximate half-life of AFP is 5 to 7 days. A nonseminoma, therefore, is associated with elevated serum concentrations of AFP. When patients with a histologically "pure" testicular seminoma have an elevated level of AFP, it is generally assumed that an undetected focus of nonseminoma is present.<sup>2,3</sup> An elevated serum concentration of beta-HCG, which has a half-life of approximately 1–3 days, may also be present with seminomatous and nonseminomatous tumors. The elevations of beta-HCG need to be interpreted with caution as hypogonadism and marijuana use may cause benign serum elevations of beta-HCG.



Nonseminoma is the more clinically aggressive tumor. When both seminoma and elements of a nonseminoma are present, management follows that for a nonseminoma. Therefore, the diagnosis of a seminoma is restricted to pure seminoma histology and a normal serum concentration of AFP.

More than 90% of patients diagnosed with GCTs are cured, including 70% to 80% of patients with advanced tumors who are treated with chemotherapy. A delay in diagnosis correlates with a higher stage at presentation. Standard therapy has been established at essentially all stages of management and must be closely followed to ensure the potential for cure.

### Clinical Presentation

A painless solid testicular mass is pathognomonic for testicular tumor. More often, patients present with testicular discomfort or swelling suggestive of epididymitis or orchitis. A trial of antibiotics may be given in this circumstance, but persistent tenderness, swelling, or any palpable abnormality warrants further evaluation.

### Diagnosis and Workup

If an intratesticular mass is identified, complete blood count, creatinine, electrolytes and liver enzymes should be obtained. Further evaluation includes measurement of the serum tumor markers, and a chest x-ray. Testicular ultrasound serves to confirm the presence of a testicular mass and to explore the contralateral testis. It is sensitive and has an important role in determining whether a mass is intra- or extratesticular.<sup>4</sup>

Serum tumor markers are critical in the assignment of prognosis and management during treatment as well. Serum tumor markers are prognostic factors and contribute to diagnosis and staging.<sup>5</sup> Markers

are assessed before orchiectomy and repeated after orchiectomy. Elevated values of beta-HCG, LDH, or AFP should be followed up with repeated tests to allow precise staging.

Biopsy may also be considered if a suspicious intratesticular abnormality, such as a hypoechoic mass or macrocalcification, is identified on ultrasound. In contrast, if microcalcifications without any other abnormality can be observed, testicular biopsy is not necessary.

In patients of reproductive age, sperm banking must be discussed.<sup>6, 7</sup> It must be discussed with the patients before undergoing any therapeutic intervention that may compromise fertility, including surgery, radiation therapy, and chemotherapy.<sup>8-10</sup> If banking of sperm is desired, it may be performed either before or after orchiectomy but certainly prior to subsequent therapy.

Inguinal orchiectomy is considered the primary treatment for most patients who present with a suspicious testicular mass.<sup>11</sup> An open inguinal biopsy of the contralateral testis is not routinely performed, but can be considered when a cryptorchid testis or marked atrophy is present.<sup>12</sup> The extent of primary tumor is classified after orchiectomy, and therefore pathological (p) stage is assigned to the primary tumor (T).

Further management is dictated by histology, a diagnosis of pure seminoma or nonseminoma (includes mixed seminoma tumors and seminoma histology with elevated AFP), and the stage. Though rare, when a patient presents with rapidly increasing beta-hCG, symptoms related to disseminated disease and a testicular mass, chemotherapy can be initiated immediately without waiting for a biopsy diagnosis.

### Risk Classification for Advanced Disease

In 1997, the International Germ Cell Cancer Consensus Group (IGCCCG) defined a prognostic factor-based classification system based on identification of some clinically independent prognostic features such as extent of disease and levels of serum tumor markers post-orchietomy. Post-orchietomy markers are utilized to classify the patient according to the IGCCCG risk classification. This classification categorizes patients with pure seminoma and non-seminoma GCT into good-, intermediate-, or poor-risk groups.<sup>13</sup>

Definition of stage and risk classification is done according to the American Joint Committee on Cancer (AJCC) and IGCCCG classification.

### Pure Seminoma

If a GCT is found, an abdominopelvic computed tomographic (CT) scan is performed. Abdominopelvic CT scanning is used to assess the retroperitoneal nodes.<sup>14</sup>

A chest CT is indicated if the abdominopelvic CT shows retroperitoneal adenopathy or the chest x-ray shows abnormal results. A chest CT scan is a sensitive way to evaluate the thorax and mediastinal nodes.<sup>15</sup>

The NCCN panel members recommend a brain MRI or bone scan, only if there is suspicion of metastases to these organs.

Elevated values of beta-HCG, LDH, or AFP should be followed with repeated tests. Serum concentrations of beta-HCG and LDH may be elevated in patients with seminoma. An elevated AFP level indicates nonseminoma, and the patient should be managed accordingly. Initial management of pure seminoma involves a radical inguinal orchietomy. Orchietomy is both diagnostic and therapeutic. Patients with

seminoma arising from an extragonadal site, such as the mediastinum, are treated with standard chemotherapy regimens according to risk status.

### Pure Seminoma Stages IA and IB

#### Primary treatment for pure seminoma stages IA and IB

For patients with stages IA and IB pure seminoma, the standard treatment options after initial orchietomy include surveillance, radiotherapy, or chemotherapy with 1 or 2 cycles of carboplatin. The disease specific survival for stage I disease is 99% irrespective of the management strategy used.<sup>16</sup> A number of prospective non-randomized studies of surveillance have been conducted.<sup>17-20</sup> The relapse rate seen in these studies is 15-20% at 5 years, and most of the relapses are first detected in infra-diaphragmatic lymph nodes.<sup>18-20</sup> Some studies report tumor size greater than 4 cm and rete testis invasion as a risk factor in predicting relapse in patients.<sup>19, 21, 22</sup> A validation study by Chung et al revealed that tumor size >4 cm and rete testis invasion were not predictors of relapse.<sup>23, 24</sup> Therefore, the NCCN panel members discourage risk-adapted management using tumor size >4 cm and rete testis invasion for stage I pure seminoma. Surveillance is listed as the preferred option (category 1) for patients with pT1 and pT2 disease by the NCCN Testicular Cancer panel.

If surveillance is not applicable, alternatives are either adjuvant carboplatin or adjuvant radiotherapy as described below. Each approach has distinct advantages and disadvantages. The physicians should discuss these with the patients and their families and pick the best approach on a case- by- case basis.

Oliver et al reported on the results of a trial that randomized 1477 patients with stage 1 testicular cancer to undergo either radiotherapy or one injection of carboplatin.<sup>25</sup> In the study, carboplatin (area under the

cure [AUC] X 7) was administered given intravenously. The dose was calculated by the formula  $7 \times (\text{glomerular filtration rate [GFR, mL/min]} + 25 \text{ mg})$ . With a median follow-up of 4 years, the relapse-free survival rates for both groups were similar.<sup>25</sup> Late relapses and secondary GCTs can occur beyond 5 and 10 years. Therefore, the investigators continued to follow these patients. The updated results reported non-inferiority of single-dose carboplatin versus radiation therapy.<sup>26</sup> In an intent-to-treat analysis, the relapse free rates at 5 years were 94.7% for the carboplatin arm and 96% for the radiotherapy arm (hazard ratio, 1.25;  $P = 0.37$ ). There were 2 cases of contralateral GCTs on carboplatin versus 15 on radiation therapy with hazard ratio of 0.22; the contralateral GCT-free rates at 5 years are 99.8% and 98.8%, respectively. The authors concluded that a single dose of carboplatin is less toxic and as effective in preventing disease recurrence as adjuvant radiotherapy in men with stage I pure seminoma after orchiectomy.<sup>26</sup> Two courses of adjuvant carboplatin have also been reported to reduce the relapse rate.<sup>27</sup> The NCCN Testicular Cancer panel recommends carboplatin AUC X 7 either 1 or 2 cycles as a category 1 recommendation for patients with stages IA and IB pure seminoma.

If radiation therapy is delivered, the NCCN panel recommends a total dose of 20.0 Gy (midplane) in 10 daily 2.0 Gy fractions,<sup>28</sup> given to an infradiaphragmatic area, including para-aortic lymph nodes; in special circumstances, it may include the ipsilateral ilioinguinal nodes.<sup>29-32</sup> Patients for whom radiation therapy is generally not given include those with patients at higher risk for morbidity from radiation therapy such as those with a history of pelvic surgery. Prophylaxis to the mediastinum is not provided, because relapse rarely occurs at this site. For patients with stages IA and IB pure seminoma, adjuvant radiation therapy to include para-aortic nodes is also a category 1 recommendation in the NCCN Testicular Cancer Guidelines, though active surveillance is

preferred (see page entitled “Principles of Radiotherapy for Treatment of Pure Seminoma” in the algorithms).

### *Follow-up after primary treatment for pure seminoma stages IA and IB*

For follow-up, it is important to distinguish the different risk of recurrence associated with each treatment modality (surveillance versus adjuvant therapy). An analysis of more than 5,000 stage I seminoma patients from various trials showed that independent of the treatment modality, the risk of recurrence is highest in the first 2 years and decreases after that.<sup>33</sup>

Follow-up for patients on surveillance includes a history and physical, with measurement of post -orchiectomy serum tumor markers (AFP, beta-HCG, and LDH), performed every 3 to 4 months for 1-2 years, every 6-12 months for years 3-4, and annually thereafter.<sup>34, 35</sup>

There is controversy regarding how many imaging studies must be performed in patients on active surveillance. The NCCN panel recommends abdominal/ pelvic CT every 6 months for years 1-2, every 6-12 months for year 3, and then annually for years 4-5. The most common site of relapse in patients managed by surveillance or adjuvant chemotherapy is the retroperitoneal nodes. Chest x-rays may be obtained as clinically indicated for years 1-5. A clinical trial in UK, entitled TRISST (MRC TE24/TRial of Imaging and Schedule in Seminoma Testis), is currently studying whether a reduced CT schedule or MRI could be used as a safe and effective alternative to standard CT-based surveillance in the management of stage I seminoma.<sup>36</sup>

The risk of recurrence 5 years after adjuvant treatment is <0.3% annually.<sup>33</sup> Follow-up of patients treated with carboplatin includes a history and physical, with measurement of post -orchiectomy serum

tumor markers (AFP, beta-HCG, and LDH) performed every 3 months the first year, every 4 months the second year, every 6 months the third year and annually thereafter.

The NCCN panel recommends abdominal/pelvic CT annually for the first 3 years after RT or carboplatin. In a recently published meta-analysis of 2,466 patients, Mead et al reported that recurrence rarely occurred after more than 3 years from treatment with either RT or carboplatin.<sup>16</sup> Relapse occurred after 3 years only in 4 out of the 2,466 patients (0.2%).<sup>16</sup> They recommend that CT scans of the pelvis and chest can be omitted in these patients as a part of routine follow-up. The NCCN panel recommends that chest x-rays be obtained only as clinically indicated.

Follow-up of patients treated with radiotherapy includes a history and physical, with measurement of post-orchietomy serum tumor markers (AFP, beta-HCG, and LDH). Follow-up should be performed every 4 months for 1-2 years, and then annually for 3-10 years.<sup>33</sup> Para-aortic radiation therapy is recommended when patients with stage I seminoma are irradiated (see page entitled “Principles of Radiotherapy for Treatment of Pure Seminoma” in the algorithms). Patients treated with para-aortic radiation therapy have a slightly higher rate of pelvic relapse compared with those treated with “dog-leg” RT.<sup>30, 33, 37, 38</sup> Some NCCN Institutions obtain a CT scan of the pelvis only every 6 months for 3 years after paraaortic radiotherapy.<sup>33</sup> Other NCCN institutions obtain CT scans of the pelvis and abdomen annually for 3 years.<sup>30</sup> The panel’s consensus recommendation is for abdominal and pelvic CT scans annually for 3 years in patients treated with para-aortic radiotherapy. Chest x-rays should be obtained only when clinically indicated. Recurrences are treated according to the stage at relapse.<sup>16</sup>

### **Pure Seminoma Stage IS**

#### *Primary treatment for pure seminoma stage IS*

By the AJCC definition, stage IS requires persistent elevation of serum tumor markers (LDH, AFP, and beta-HCG) following orchietomy. Stage IS is uncommon and patients are generally treated with radiation to an infradiaphragmatic area, including para-aortic lymph nodes with or without radiation to the ipsilateral ilioinguinal nodes.<sup>30-32</sup>

#### *Follow-up after primary radiation treatment for pure seminoma stage IS*

Follow-up recommendations by the NCCN panel for patients with stage IS treated with adjuvant radiation therapy are similar to those for patients with stages IA and IB treated with adjuvant radiation therapy. Recurrences are treated according to the stage at relapse.

### **Pure Seminoma Stages IIA and IIB**

#### *Primary treatment for pure seminoma stages IIA and IIB*

Stage IIA is defined as metastatic disease to lymph nodes, with a lymph node mass measuring less than 2 cm in diameter in greatest dimension on CT scan, and stage IIB as disease measuring 2 to 5 cm in maximum diameter.

Radiotherapy has been the mainstay of treatment in stage IIA and IIB seminoma patients.<sup>39-41</sup> The standard radiation field compared with stage I is extended from the para-aortic region to include an ipsilateral iliac field. The relapse rates are moderate (5-6% for stage IIA), and overall survival is almost 100%.<sup>39, 41, 42</sup>

For patients with stage IIA or IIB seminoma, the NCCN Testicular Cancer panel recommends radiation therapy to an infradiaphragmatic area, including para-aortic and ipsilateral iliac lymph nodes in two anteroposterior-posteroanterior phases. The initial phase consists radiation to modified dog-leg fields consisting of a dose of 20.0 Gy



(midplane) in 10 daily 2.0 Gy fractions<sup>29</sup> or 25.5 Gy in 15 daily 1.7 Gy fractions.<sup>43</sup> The panel prefers modified ‘dog-leg’ fields as described by Classen et al.<sup>39</sup> For details on field arrangement, see page entitled “Principles of Radiotherapy for Treatment of Pure Seminoma” in the algorithms. The second phase (cone down) of radiotherapy consists of daily 2.0 Gy fractions to a cumulative total dose of approximately 30 Gy for stage IIA and 36 Gy for stage IIB.<sup>39</sup> As with the management of stage I disease, prophylactic mediastinal radiation therapy is not indicated for stage II disease.<sup>44</sup>

For selected stage IIB seminoma patients such as those with adenopathy measuring more than 3 cm,<sup>45</sup> chemotherapy with 4 courses of etoposide and cisplatin (EP) or 3 cycles of bleomycin, etoposide, and cisplatin (BEP) is an alternative to radiotherapy.<sup>42, 46</sup>

### *Follow-up for stages IIA and IIB pure seminoma after primary treatment*

The recommended follow-up schedules for stage IIA/B patients after radiation therapy include a history and physical with measurement of post-orchietomy serum tumor markers (AFP, beta-HCG, and LDH), performed every 3 months for year 1, every 6 months for years 2-5, and then annually for years 6-10.

Chest x-ray is recommended every 6 months for the first 2 years. An abdominal CT scan is recommended every 6 months in years 1-2 and annually in year 3 after radiotherapy. In those who have undergone retroperitoneal lymph node dissection (RPLND), it is recommended between 3-6 months post surgery and then as clinically indicated.<sup>39</sup>

The follow-up of stage IIB patients after chemotherapy is similar to follow-up after chemotherapy for patients with stages IIC and III as discussed in the section below entitled “Follow-up for pure seminoma stages IIB, IIC, and III after chemotherapy”

### **Pure Seminoma Stages IIC and III**

#### *Primary treatment for pure seminoma stages IIC and III*

Patients with stage IIC or III disease are those considered at either good or intermediate risk. All stage IIC and stage III seminoma is considered good-risk disease except for stage III disease with non-pulmonary visceral metastases (e.g., bone, liver, or brain), which is considered intermediate risk. Standard chemotherapy is used for both groups of patients. However, for patients with good risk, 3 cycles of BEP<sup>47-49</sup> or 4 cycles of EP<sup>50-52</sup> are recommended. In contrast, more intensive chemotherapy, i.e., 4 cycles of BEP, is recommended for those with intermediate risk disease.<sup>53, 54</sup> All these chemotherapy options are category 1 recommendations according to the NCCN Testicular Cancer panel.

#### *Post-chemotherapy management of pure seminoma stages IIB, IIC, and III*

After initial chemotherapy, patients with stage IIB, IIC and III are evaluated with serum tumor markers and a CT scan of the chest abdomen and pelvis. Patients are then classified according to the presence or absence of a residual mass and the status of serum tumor markers. Patients with normal markers and either no residual mass or residual mass of 3 cm or lesser need no further treatment. They should undergo surveillance as discussed in the section below entitled “Follow-up for pure seminoma stages IIB, IIC, and III after chemotherapy”

In cases of residual tumor >3 cm and markers levels that are normal, a PET scan is recommended to assess whether there is residual viable tumor.<sup>55</sup> A PET scan has a high positive and negative predictive value with regard to the question of remaining disease in patients with residual masses after chemotherapy.<sup>56</sup> To reduce the incidence of false positive results, the PET scan is typically performed at least 6 weeks after completion of chemotherapy. Notably, granulomatous disease,

such as sarcoid, is a source of false positive results. The NCCN panel recommends a PET scan in patients with seminoma, a residual mass >3 cm and normal levels of markers, approximately 6 weeks after chemotherapy in order to decide whether to continue with surveillance or resume treatment.<sup>55, 57-61</sup>

If the PET scan is negative, no further treatment is needed; however, the patient should undergo follow-up<sup>62, 63</sup> as discussed in the section below entitled “Follow-up for pure seminoma stages IIB, IIC, and III after chemotherapy”.

Since a positive PET scan is strong indicator of residual active tumor, resection should be considered. Therefore, if technically feasible, RPLND may be considered (category 2A). The other option if resection is not feasible is second-line chemotherapy (category 2A). Cisplatin-based combination chemotherapy is used for second-line treatment.<sup>64-66</sup> The regimens are four cycles of TIP (paclitaxel, ifosfamide, cisplatin)<sup>67</sup> or four cycles of VeIP (vinblastine, ifosfamide, cisplatin).<sup>65, 66</sup>

According to the NCCN Guidelines, second-line therapy for seminoma and nonseminoma is similar. It is discussed below in the section entitled “Second-line therapy for Metastatic Germ Cell Tumors”. The follow-up of these patients is also described below.

*Follow-up for pure seminoma stages IIB, IIC, and III after chemotherapy*  
Recommended follow-up schedules include a history and physical with chest x-ray and measurement of post- orchiectomy serum tumor markers every 2 months for the first year, every 3 months for the second year, every 6 months for the third and fourth years and annually thereafter through the tenth year. An abdominal/pelvic CT scan is recommended as clinically indicated in all cases except in those who

have undergone RPLND. In this situation, it is recommended between 3-6 months post surgery and then as clinically indicated.<sup>68</sup> A PET scan may be performed as clinically indicated.

### Nonseminoma

Similar to the workup for seminoma, if non-seminoma is found, CT of abdomen and pelvis should be performed with chest imaging if needed. MRI of the brain and bone scan should be conducted in the case of clinical indicators (symptoms) of involvement. PET scanning does not contribute and routine use is not recommended for nonseminoma patients.<sup>69, 70</sup>

Elevated values of beta-HCG, LDH, or AFP should be followed up with repeated tests. Nonseminoma includes mixed seminoma tumors and seminoma histology with elevated AFP. Post-orchietomy serum markers are important to classify the patient with nonseminoma according to the IGCCCG risk classification into good-, intermediate- and poor-risk groups.<sup>13</sup>

In patients of reproductive age, sperm banking must be discussed.<sup>6, 7</sup> It must be discussed with the patients before undergoing any therapeutic intervention that may compromise fertility, including surgery, radiation therapy, or chemotherapy.<sup>8-10</sup> If sperm banking is desired, it may be performed either before or after orchiectomy, but certainly prior to adjuvant therapy.

Stage dependent treatment options after inguinal orchiectomy include surveillance, chemotherapy, and RPLND. Although the timing of the RPLND may vary, most patients with nonseminoma will undergo an RPLND for either diagnostic or therapeutic purposes at some point during treatment. The major morbidity associated with bilateral

dissection is retrograde ejaculation, resulting in infertility. Nerve dissection techniques preserve antegrade ejaculation in 90% of cases.<sup>71</sup>

### **Nonseminoma Stage IA**

#### *Primary treatment of nonseminoma stage IA*

According to the NCCN Testicular Cancer panel, two management options exist for patients with stage IA disease after orchiectomy: (1) surveillance<sup>72-76</sup> (2) nerve-sparing RPLND. The cure rate with either approach exceeds 95%. However, the high cure rate associated with surveillance depends on adherence to periodic follow-up examinations and subsequent chemotherapy for the 20% to 30% of patients who experience relapse. Patients who choose surveillance should agree to be compliant for follow-up. When RPLND is performed, it should be done using a nerve-sparing technique.<sup>77,78</sup> According to the NCCN Guidelines, the nerve-sparing RPLND is recommended within 4 weeks of a CT scan and within 7 to 10 days of repeat serum marker testing to ensure accurate presurgical staging.

#### *Management of nonseminoma stage IA after RPLND*

After RPLND, if the dissected lymph nodes are not involved with a tumor (pN0), no adjuvant chemotherapy is given. The patients should undergo surveillance. However, if the resected lymph nodes involve tumor, the decision whether to use adjuvant chemotherapy is based on the degree of nodal involvement. Surveillance is preferred over chemotherapy for patients with pN1 disease. Chemotherapy is preferred in patients with pN2 or pN3 disease. Surveillance is an option for patients with pN2 but not an option for patients with pN3 disease. Recommended chemotherapy regimens include either EP or BEP. Two cycles of either regimen (EP or BEP) are recommended for patients with pN1 or pN2 disease.<sup>79-85</sup> For patients with pN3 disease, longer

courses of chemotherapy with 4 cycles of EP or 3 cycles of BEP is recommended.

#### *Follow-up for nonseminoma stage IA*

In the current NCCN Guidelines, the long term follow-up tests for stage IA patients, electing primary surveillance, post-RPLND, or post-chemotherapy include serum marker assessment, chest x-ray, and an abdominal CT scan. The frequency of these tests is outlined in the NCCN Testicular Cancer treatment algorithms on page entitled "Follow-up for Nonseminoma".

### **Nonseminoma Stage IB**

#### *Primary treatment of nonseminoma stage IB*

After orchiectomy, either nerve-sparing RPLND or adjuvant chemotherapy is an option to reduce the risk of relapse in patients with stage IB disease.

Several studies using two cycles of BEP as primary treatment for stage I nonseminoma patients have been reported with relapse-free survival in greater than 95% of patients.<sup>76, 82, 86-90</sup> Based on these studies the NCCN panel considers 2 cycles of BEP as primary chemotherapy as a category 2A recommendation. Late consequences of cisplatin-based chemotherapy have been reported based on long-term follow-up of patients.<sup>91-96</sup> A trial by Albers et al randomized stage I patients after orchiectomy, to undergo unilateral RPLND (n = 191) or one adjuvant course of BEP (n = 191).<sup>97</sup> After a median follow-up of 4.7 years two relapses were reported in the group of patients treated with one course of adjuvant BEP and 13 patients with relapse in the arm treated with RPLND (P = .0011). This study indicates that one course of BEP is active in patients and could be an option in patients unable to tolerate the toxicity of treatment. The comparator arm in this trial (unilateral

RPLND) is not the standard treatment approach. Therefore while the results of this study are promising however this merits further investigation comparing 1 cycle of BEP versus 2 cycles with longer follow-up. The NCCN panel considers 1 cycle of BEP a category 2B option as primary therapy.

Surveillance alone may be offered to selected patients with T2 disease (category 2B). Vascular invasion is a significant predictor of relapse when orchiectomy is followed by surveillance alone.<sup>11</sup> Surveillance is generally not recommended for T2 disease with vascular invasion because of the 50% chance of relapse. Exceptions are made according to individual circumstances. When surveillance is opted in selected patients with T2 disease, both the patient and the physician must be compliant with follow-up recommendations.

### *Management of nonseminoma stage 1B after primary treatment*

The adjuvant treatment following primary nerve-sparing RPLND for patients with IB is similar to that described for stage IA in the section above entitled “Management of nonseminoma stage 1A after RPLND”

Management after primary chemotherapy in patients with normal values of serum tumor markers may be nerve-sparing RPLND or surveillance. The NCCN Testicular Cancer panel considers, nerve-sparing bilateral RPLND a category 2A recommendation for patients with residual mass of 1 cm or greater and category 2B if the residual mass is less than 1 cm. Surveillance is category 2B for both populations. The long term follow-up tests in the current NCCN Guidelines for those electing surveillance include serum marker assessment, chest x-ray, and abdominal CT scan. The frequency of these tests is outlined in the NCCN Testicular Cancer treatment algorithms on page entitled “Follow-up for nonseminoma”.

### **Nonseminoma Stage IS**

Patients with stage IS disease exhibit a persistent elevation of serum tumor markers post-orchietomy but no radiographic evidence of disease. The elevated levels of AFP and beta-HCG after orchietomy must be interpreted with caution as they might be due to reasons other than disseminated nonseminoma such as hepatobiliary disease, marijuana use, and hypogonadism.

#### *Primary treatment of nonseminoma stage IS*

The consensus recommendation of the NCCN panel is that these patients be treated with standard chemotherapy with either 4 cycles of EP or 3 cycles of BEP. Either regimen is preferable to initial RPLND because these patients nearly always have disseminated disease.<sup>98, 99</sup>

#### *Management of stage 1S nonseminoma post-primary treatment*

The management of patients with stage IS nonseminoma after primary treatment with chemotherapy is similar to the management schema outlined for good risk nonseminoma patients including stages IIB, IIC and IIIA described in sections below (see page MS-11).

### **Nonseminoma Stage IIA**

#### *Primary treatment of nonseminoma stage IIA*

Treatment for patients with stage IIA nonseminoma depends on post-orchietomy serum tumor marker levels.

For patients with normal post-orchietomy levels of AFP and HCG, the NCCN panel considers either primary RPLND (category 2A) or chemotherapy (category 2B) and as treatment options for stage IIA.<sup>100-104</sup> The chemotherapy regimens include 4 cycles of EP or 3 cycles of BEP. Chemotherapy is considered particularly appropriate if the patient has multifocal disease.



For patients with persistently elevated AFP or HCG levels, the NCCN panel recommends induction chemotherapy. The data supporting this comes from 2 retrospective studies of patients with low stage nonseminoma treated by RPLND.<sup>105, 106</sup> The presence of elevated postorchietomy AFP or HCG levels was associated with a high risk of relapse.<sup>105, 106</sup>

Management after primary chemotherapy and RPLND is discussed in sections below.

### *Management after primary treatment of nonseminoma stage IIA*

After primary chemotherapy, the subsequent management depends on marker levels and the residual mass on CT scan. Therefore the patients must undergo a CT scan before treatment decisions. Lesions less than 1 cm on CT scan may represent false positives and must be interpreted with caution. The options listed for managing stage IIA patients after primary chemotherapy, by the NCCN panel, include nerve-sparing bilateral RPLND or surveillance.

The NCCN Testicular Cancer panel considers nerve-sparing bilateral RPLND a category 2A recommendation for patients with residual mass of 1 cm or greater and category 2B if the residual mass is less than 1 cm. A bilateral RPLND involves removal of lymphatic tissue between both ureters, spanning from the diaphragmatic crus to the bifurcation of the common iliac arteries. The rationale for this extended region of dissection is the greater likelihood of bilateral disease with greater tumor burden.<sup>107</sup> Referral to high volume centers must be considered for RPLND post-chemotherapy. Surveillance however is category 2B for both populations.

After primary nerve-sparing RPLND, the treatment options include either surveillance or chemotherapy. The treatment choice depends on

treatment depends on the number of positive lymph nodes identified. For example, since RPLND is likely a curative procedure in patients with pathological stage N0 (pN0) surveillance is the only option listed for this group. Surveillance and chemotherapy are options for patients with pN1 and pN2 disease. RPLND is a curative procedure in 60%-90% of pN1 patients,<sup>106, 108, 109</sup> therefore the NCCN panel prefers surveillance over chemotherapy for patients with pN1 disease. The risk of relapse in patients with p N2-N3 disease is > 50%.<sup>106, 108, 110</sup> With 2 cycles of adjuvant cisplatin based chemotherapy, the risk of relapse after RPLND is generally <1%.<sup>106, 111, 112</sup> The NCCN panel prefers 2 cycles of adjuvant chemotherapy for pN2 disease; and full course chemotherapy (not surveillance) is recommended for pN3 disease. Recommended adjuvant chemotherapy regimens for pN1 and pN2 consists of 2 cycles of BEP or 2 cycles of EP,<sup>113</sup> resulting in a nearly 100% relapse-free survival rate. For pN3, the NCCN panel recommend longer chemotherapy course consisting of either 4 cycles of EP or 3 cycles of BEP.

If stage IIA patients have persistent marker elevation (i.e., stage IIA, S1), the primary treatment is chemotherapy as described for good-risk nonseminoma in sections below (see page MS-11).

### **Nonseminoma Stage IIB**

#### *Primary treatment of nonseminoma stage IIB*

Treatment for patients with stage IIB nonseminoma depends also on both post-orchietomy tumor marker levels *and* radiographic findings. When tumor markers are negative, the CT findings determine the proper course of treatment. If abnormal radiographic findings are limited to sites within the lymphatic drainage in the retroperitoneum (i.e., the landing zone), two management options are available. One option is to perform nerve- sparing RPLND and to consider adjuvant treatment as



described for patients with stage IIA disease. The second option is to treat with primary chemotherapy with either 4 cycles of EP or 3 cycles of BEP, followed by nerve-sparing RPLND or surveillance.

Both options of primary chemotherapy or primary RPLND are comparable options in terms of outcome but side-effects and toxicity are different.<sup>101</sup> The reported relapse free survival with either approach is close to 98%.<sup>108, 113-118</sup>

If metastatic disease (based on radiographic findings) is not confined to the lymphatic drainage (i.e., multifocal lymph node metastases outside the lymphatic drainage sites), chemotherapy is recommended with either 4 cycles of EP or 3 cycles of BEP, followed by nerve-sparing RPLND or surveillance.

For stage IIB patients with persistent marker elevation (stage IIB, S1), the primary treatment is chemotherapy as described for good-risk nonseminoma including stages IS, IIC and IIIA in sections below (see section below). Initial RPLND is not recommended in this situation.

#### *Management after primary treatment of nonseminoma stage IIB*

The management of patients with stage IIB nonseminoma after primary treatment with either nerve-sparing bilateral RPLND or chemotherapy is similar to the management scheme post-primary outlined above for patients with stage IIA nonseminoma.

#### **Advanced Metastatic Nonseminoma**

The primary chemotherapy regimens of choice for patients with advanced disease depends on the IGCCCG risk classification.<sup>13</sup> This classification categorizes patients as good-, intermediate-, or poor-risk.<sup>13</sup> Also, patients with an extragonadal primary site, whether retroperitoneal or mediastinal, are treated with initial chemotherapy.

#### *Primary treatment of good-risk nonseminoma*

Based on the IGCCCG good-risk classification, this group includes patients with stages IS, IIA and IIB (with persistent marker elevation), IIC, and IIIA. Treatment for good-risk GCTs were designed to decrease toxicity while maintaining maximal efficacy. Randomized clinical trials showed that this can be achieved by either substituting etoposide for vinblastine<sup>119, 120</sup> or by eliminating or reducing the dose of bleomycin.<sup>119, 121</sup> Presently, two regimens are recommended by the NCCN Testicular Cancer panel: 4 cycles of EP<sup>51</sup> or 3 cycles of BEP<sup>47, 49, 122, 123</sup> (both category 2A). Either regimen is well tolerated and cures approximately 90% of patients with good risk.<sup>124</sup>

#### *Primary treatment of intermediate-risk (stage IIIB) nonseminoma*

For patients with intermediate risk, the cure rate is approximately 70% with standard therapy using 4 cycles of BEP.<sup>125, 126</sup> For patients with intermediate risk (stage IIIB), 4 cycles of BEP is a category 2A recommendation by the NCCN Testicular Cancer panel.

#### *Primary treatment of poor-risk (stage IIIC) nonseminoma*

In patients with poor-risk GCTs (stage IIIC), between 20% and 30% of all patients with metastatic GCTs are not cured with conventional cisplatin therapy and less than one half experience a durable complete response to 4 cycles of BEP, and therefore treatment in a clinical trial is preferred.<sup>124</sup> The NCCN panel lists enrolling these patients in clinical trials as their preferred treatment option.

The standard chemotherapy regimen for poor-risk patients is 4 cycles of BEP. The regimen containing etoposide, ifosfamide, cisplatin (VIP) was compared to BEP and found to be more toxic, compared with BEP but equally effective. Therefore 4 cycles of VIP may be used for those who may not tolerate bleomycin.<sup>127</sup>

### *Post-chemotherapy management for good-, intermediate-, and poor-risk nonseminoma*

At the conclusion of induction chemotherapy, CT scans of the abdomen and pelvis are indicated, along with serum tumor marker assays. PET scans for residual disease have limited predictive value. The frequency of these tests is outlined in the NCCN Testicular Cancer treatment algorithms on page entitled “Follow-up for Nonseminoma”.

If a complete response to chemotherapy is found by radiographic imaging, and the tumor markers are negative, the NCCN panel lists 2 management options exist: surveillance (category 2B) or bilateral RPLND using nerve-sparing technique if possible (category 2B).<sup>63</sup>

If a residual mass is found and the serum tumor markers (AFP and beta-HCG) have normalized, then all sites of residual disease are resected.<sup>128-130</sup> If only necrotic debris or mature teratoma is encountered, no further therapy is necessary and patients must be put under surveillance. If embryonal, yolk sac, choriocarcinoma, or seminoma elements, is found in the residual mass, 2 cycles of conventionally dosed chemotherapy (EP, VeIP [paclitaxel, ifosfamide, cisplatin], or TIP [vinblastine, ifosfamide, cisplatin]) are administered.

After patients are rendered disease-free, standard surveillance is initiated. The frequency of these follow-up tests is outlined in the NCCN Testicular Cancer treatment algorithms on page entitled “Follow-up for Nonseminoma”.

Patients who experience an incomplete response to first-line therapy are treated with second-line therapy (see section below). The NCCN Testicular Cancer panel prefers that patients with recurrent

nonseminoma be treated at centers with expertise in the management of this disease.

### **Second Line Therapy for Metastatic Germ Cell Tumors**

Patients who do not experience a durable complete response to first-line therapy or those who experience a recurrence can be divided into those with a favorable or unfavorable prognosis based on prognostic factors. Prognostic factors can be used in deciding whether a patient is a candidate for conventional dose therapy or high-dose therapy with stem cell support as a second-line option. To determine the prognosis at initial diagnosis, the IGCCCG classification is used. However, for patients with progressive or relapsed disease after first-line treatment, several prognostic models have been reported.<sup>131-133</sup> Favorable prognostic factors to conventional dose second-line chemotherapy include a testicular primary site, prior complete response to first-line therapy, low levels of post- orchiectomy serum tumor markers, and low-volume disease.<sup>131</sup> Standard second-line therapy includes conventional dose chemotherapy or high -dose chemotherapy. The conventional dose regimen include cisplatin and ifosfamide combined with either vinblastine or paclitaxel.<sup>134</sup> If the patient experiences an incomplete response or relapses after second-line conventional dose chemotherapy, the preferred third-line option, if the second- line therapy included conventional dose chemotherapy, would be high-dose chemotherapy<sup>135, 136</sup> or chemotherapy in the context of a clinical trial.

Unfavorable prognostic features include incomplete response to first-line treatment, high levels of serum markers, high volume disease and presence of extratesticular primary tumor. Patients with a testicular primary site and rising post -orchiectomy serum tumor markers during



first-line therapy are usually considered for high-dose programs. Chemotherapy options for patients with poor prognostic features include chemotherapy in the context of a clinical trial; conventional-dose second line therapy (with VeIP or TIP); high-dose chemotherapy (category 2B). Alternatively, the patients may be put on best supportive care or salvage surgery if feasible.

The high-dose regimens include high-dose carboplatin plus etoposide followed by autologous stem cell transplant<sup>132, 137</sup> or paclitaxel, ifosfamide followed by high-dose carboplatin plus etoposide with stem cell support.<sup>138</sup>

For patients who do not experience complete response to second-line high-dose therapy, the disease is nearly always incurable; the only exception is the rare patient with elevated serum tumor markers and a solitary site of metastasis (usually retroperitoneal) that undergoes surgical resection.<sup>139</sup> Other options are participation in a clinical trial or best supportive care.

#### *Palliative therapy*

All patients with either persistent or recurrent disease should be considered for palliative chemotherapy or radiation therapy.

The palliative chemotherapy options for patients with intensively pretreated, cisplatin-resistant, or refractory germ cell tumor are combinations of gemcitabine with paclitaxel and /or oxaliplatin.<sup>140-145</sup>

The recommendation for gemcitabine and oxaliplatin is based on data from phase II studies.<sup>140-142</sup> These studies investigated the efficacy and the toxicity of gemcitabine and oxaliplatin (GEMOX) in patients with relapsed or cisplatin-refractory GCTs. The results showed that oxaliplatin and gemcitabine combination is a safe for patients with

cisplatin-refractory testicular GCTs and may offer a chance of long-term survival.<sup>140-142</sup>

Gemcitabine and paclitaxel is another option that has shown promising results in a phase II study<sup>144</sup> and long term follow-up results with this combination show long disease-free survival in the rare patients that progressed after high-dose chemotherapy, and had not received prior paclitaxel or gemcitabine.<sup>145</sup>

A phase II study of patients with treatment-refractory germ-cell tumors found the combination of gemcitabine, oxaliplatin, paclitaxel to be effective with acceptable toxicity.<sup>143</sup>

For palliative therapy, the NCCN Testicular Cancer panel recommends gemcitabine with oxaliplatin<sup>140-142</sup>; gemcitabine with paclitaxel<sup>144, 145</sup>; gemcitabine with oxaliplatin and paclitaxel<sup>143</sup> (all are category 2A recommendations).

#### ***Treatment of Brain Metastases***

The prognosis of patients with brain metastasis is poor.<sup>146</sup> Primary chemotherapy (using a cisplatin-based regimen) with radiotherapy is indicated for patients in whom brain metastases are detected.<sup>147, 148</sup> If clinically indicated and feasible, surgical resection of the metastasis should also be performed.





## References

1. Siegel R, Naishadham D, Jemal A. Cancer statistics, 2012. CA: A Cancer Journal for Clinicians 2011. Available at: <http://dx.doi.org/10.3322/caac.20138>.
2. Nazeer T, Ro JY, Amato RJ, et al. Histologically pure seminoma with elevated alpha-fetoprotein: a clinicopathologic study of ten cases. Oncol Rep 1998;5:1425-1429. Available at: <http://www.ncbi.nlm.nih.gov/pubmed/9769381>.
3. Weissbach L, Bussar-Maatz R, Mann K. The value of tumor markers in testicular seminomas. Results of a prospective multicenter study. Eur Urol 1997;32:16-22. Available at: <http://www.ncbi.nlm.nih.gov/pubmed/9266226>.
4. Kim W, Rosen MA, Langer JE, et al. US MR imaging correlation in pathologic conditions of the scrotum. Radiographics 2007;27:1239-1253. Available at: <http://www.ncbi.nlm.nih.gov/pubmed/17848688>.
5. Klein EA. Tumor markers in testis cancer. Urol Clin North Am 1993;20:67-73. Available at: <http://www.ncbi.nlm.nih.gov/pubmed/7679533>.
6. Ragni G, Somigliana E, Restelli L, et al. Sperm banking and rate of assisted reproduction treatment: insights from a 15-year cryopreservation program for male cancer patients. Cancer 2003;97:1624-1629. Available at: <http://www.ncbi.nlm.nih.gov/pubmed/12655518>.
7. Saito K, Suzuki K, Iwasaki A, et al. Sperm cryopreservation before cancer chemotherapy helps in the emotional battle against cancer. Cancer 2005;104:521-524. Available at: <http://www.ncbi.nlm.nih.gov/pubmed/15968690>.
8. Brydoy M, Fossa SD, Klepp O, et al. Paternity following treatment for testicular cancer. J Natl Cancer Inst 2005;97:1580-1588. Available at: <http://www.ncbi.nlm.nih.gov/pubmed/16264178>.
9. Huyghe E, Matsuda T, Daudin M, et al. Fertility after testicular cancer treatments: results of a large multicenter study. Cancer 2004;100:732-737. Available at: <http://www.ncbi.nlm.nih.gov/pubmed/14770428>.
10. Gordon W, Jr., Siegmund K, Stanisic TH, et al. A study of reproductive function in patients with seminoma treated with radiotherapy and orchidectomy: (SWOG-8711). Southwest Oncology Group. Int J Radiat Oncol Biol Phys 1997;38:83-94. Available at: <http://www.ncbi.nlm.nih.gov/pubmed/9212008>.
11. Jones RH, Vasey PA. Part I: testicular cancer--management of early disease. Lancet Oncol 2003;4:730-737. Available at: <http://www.ncbi.nlm.nih.gov/pubmed/14662429>.
12. Fossa SD, Chen J, Schonfeld SJ, et al. Risk of contralateral testicular cancer: a population-based study of 29,515 U.S. men. J Natl Cancer Inst 2005;97:1056-1066. Available at: <http://www.ncbi.nlm.nih.gov/pubmed/16030303>.
13. International Germ Cell Consensus Classification: a prognostic factor-based staging system for metastatic germ cell cancers. International Germ Cell Cancer Collaborative Group. J Clin Oncol 1997;15:594-603. Available at: <http://www.ncbi.nlm.nih.gov/pubmed/9053482>.
14. Leibovitch L, Foster RS, Kopecky KK, Donohue JP. Improved accuracy of computerized tomography based clinical staging in low stage nonseminomatous germ cell cancer using size criteria of retroperitoneal lymph nodes. J Urol 1995;154:1759-1763. Available at: <http://www.ncbi.nlm.nih.gov/pubmed/7563341>.
15. See WA, Hoxie L. Chest staging in testis cancer patients: imaging modality selection based upon risk assessment as determined by abdominal computerized tomography scan results. J Urol 1993;150:874-878. Available at: <http://www.ncbi.nlm.nih.gov/pubmed/8345604>.



16. Mead GM, Fossa SD, Oliver RT, et al. Randomized Trials in 2466 Patients With Stage I Seminoma: Patterns of Relapse and Follow-up. *J Natl Cancer Inst* 2011;103:241-249. Available at: <http://www.ncbi.nlm.nih.gov/pubmed/21212385>.
17. Groll RJ, Warde P, Jewett MA. A comprehensive systematic review of testicular germ cell tumor surveillance. *Crit Rev Oncol Hematol* 2007;64:182-197. Available at: <http://www.ncbi.nlm.nih.gov/pubmed/17644403>.
18. Aparicio J, Garcia del Muro X, Maroto P, et al. Multicenter study evaluating a dual policy of postorchietomy surveillance and selective adjuvant single-agent carboplatin for patients with clinical stage I seminoma. *Ann Oncol* 2003;14:867-872. Available at: <http://www.ncbi.nlm.nih.gov/pubmed/12796024>.
19. Warde P, Specht L, Horwich A, et al. Prognostic factors for relapse in stage I seminoma managed by surveillance: a pooled analysis. *J Clin Oncol* 2002;20:4448-4452. Available at: <http://www.ncbi.nlm.nih.gov/pubmed/12431967>.
20. Chung P, Parker C, Panzarella T, et al. Surveillance in stage I testicular seminoma - risk of late relapse. *Can J Urol* 2002;9:1637-1640. Available at: <http://www.ncbi.nlm.nih.gov/pubmed/12431325>.
21. von der Maase H, Specht L, Jacobsen GK, et al. Surveillance following orchidectomy for stage I seminoma of the testis. *Eur J Cancer* 1993;29A:1931-1934. Available at: <http://www.ncbi.nlm.nih.gov/pubmed/8280484>.
22. Warde P, Gospodarowicz MK, Banerjee D, et al. Prognostic factors for relapse in stage I testicular seminoma treated with surveillance. *J Urol* 1997;157:1705-1709; discussion 1709-1710. Available at: <http://www.ncbi.nlm.nih.gov/pubmed/9112510>.
23. Chung PW, Daugaard G, Tyldesley S, et al. Prognostic factors for relapse in stage I seminoma managed with surveillance: A validation study [abstract]. *J Clin Oncol* 2010;28:Abstract 4535. Available at: [http://meeting.ascopubs.org/cgi/content/abstract/28/15\\_suppl/4535](http://meeting.ascopubs.org/cgi/content/abstract/28/15_suppl/4535).
24. Chung P, Warde P. Stage I seminoma: adjuvant treatment is effective but is it necessary? *J Natl Cancer Inst* 2011;103:194-196. Available at: <http://www.ncbi.nlm.nih.gov/pubmed/21212383>.
25. Oliver RT, Mason MD, Mead GM, et al. Radiotherapy versus single-dose carboplatin in adjuvant treatment of stage I seminoma: a randomised trial. *Lancet* 2005;366:293-300. Available at: <http://www.ncbi.nlm.nih.gov/pubmed/16039331>.
26. Oliver RT, Mead GM, Rustin GJ, et al. Randomized Trial of Carboplatin Versus Radiotherapy for Stage I Seminoma: Mature Results on Relapse and Contralateral Testis Cancer Rates in MRC TE19/EORTC 30982 Study (ISRCTN27163214). *J Clin Oncol* 2011. Available at: <http://www.ncbi.nlm.nih.gov/pubmed/21282539>.
27. Aparicio J, Germa JR, Garcia del Muro X, et al. Risk-adapted management for patients with clinical stage I seminoma: the Second Spanish Germ Cell Cancer Cooperative Group study. *J Clin Oncol* 2005;23:8717-8723. Available at: <http://www.ncbi.nlm.nih.gov/pubmed/16260698>.
28. Garmezzy B, Pagliaro LC. Choosing treatment for stage I seminoma: who should get what? *Oncology (Williston Park)* 2009;23:753, 759. Available at: <http://www.ncbi.nlm.nih.gov/pubmed/19777759>.
29. Jones WG, Fossa SD, Mead GM, et al. Randomized trial of 30 versus 20 Gy in the adjuvant treatment of stage I Testicular Seminoma: a report on Medical Research Council Trial TE18, European Organisation for the Research and Treatment of Cancer Trial 30942 (ISRCTN18525328). *J Clin Oncol* 2005;23:1200-1208. Available at: <http://www.ncbi.nlm.nih.gov/pubmed/15718317>.
30. Fossa SD, Horwich A, Russell JM, et al. Optimal planning target volume for stage I testicular seminoma: A Medical Research Council randomized trial. *Medical Research Council Testicular Tumor Working*



Group. *J Clin Oncol* 1999;17:1146. Available at: <http://www.ncbi.nlm.nih.gov/pubmed/10561173>.

31. Dinniwell R, Chan P, Czarnota G, et al. Pelvic lymph node topography for radiotherapy treatment planning from ferumoxtran-10 contrast-enhanced magnetic resonance imaging. *Int J Radiat Oncol Biol Phys* 2009;74:844-851. Available at: <http://www.ncbi.nlm.nih.gov/pubmed/19095369>.

32. McMahon CJ, Rofsky NM, Pedrosa I. Lymphatic metastases from pelvic tumors: anatomic classification, characterization, and staging. *Radiology* 2010;254:31-46. Available at: <http://www.ncbi.nlm.nih.gov/pubmed/20032141>.

33. Martin JM, Panzarella T, Zwahlen DR, et al. Evidence-based guidelines for following stage 1 seminoma. *Cancer* 2007;109:2248-2256. Available at: <http://www.ncbi.nlm.nih.gov/pubmed/17437287>.

34. Souchon R, Hartmann M, Krege S, et al. Interdisciplinary evidence-based recommendations for the follow-up of early stage seminomatous testicular germ cell cancer patients. *Strahlenther Onkol* 2011;187:158-166. Available at: <http://www.ncbi.nlm.nih.gov/pubmed/21347634>.

35. Tolan S, Vesprini D, Jewett MA, et al. No role for routine chest radiography in stage I seminoma surveillance. *Eur Urol* 2010;57:474-479. Available at: <http://www.ncbi.nlm.nih.gov/pubmed/19577354>.

36. TRISST (MRC TE24) Trial of imaging and schedule in seminoma testis. Available at: [http://www.ctu.mrc.ac.uk/research\\_areas/study\\_details.aspx?s=40](http://www.ctu.mrc.ac.uk/research_areas/study_details.aspx?s=40).

37. Livsey JE, Taylor B, Mobarek N, et al. Patterns of relapse following radiotherapy for stage I seminoma of the testis: implications for follow-up. *Clin Oncol (R Coll Radiol)* 2001;13:296-300. Available at: <http://www.ncbi.nlm.nih.gov/pubmed/11554630>.

38. van As NJ, Gilbert DC, Money-Kyrle J, et al. Evidence-based pragmatic guidelines for the follow-up of testicular cancer: optimising

the detection of relapse. *Br J Cancer* 2008;98:1894-1902. Available at: <http://www.ncbi.nlm.nih.gov/pubmed/18542063>.

39. Classen J, Schmidberger H, Meisner C, et al. Radiotherapy for stages IIA/B testicular seminoma: final report of a prospective multicenter clinical trial. *J Clin Oncol* 2003;21:1101-1106. Available at: <http://www.ncbi.nlm.nih.gov/pubmed/12637477>.

40. Patterson H, Norman AR, Mitra SS, et al. Combination carboplatin and radiotherapy in the management of stage II testicular seminoma: comparison with radiotherapy treatment alone. *Radiother Oncol* 2001;59:5-11. Available at: <http://www.ncbi.nlm.nih.gov/pubmed/11295200>.

41. Schmidberger H, Bamberg M, Meisner C, et al. Radiotherapy in stage IIA and IIB testicular seminoma with reduced portals: a prospective multicenter study. *Int J Radiat Oncol Biol Phys* 1997;39:321-326. Available at: <http://www.ncbi.nlm.nih.gov/pubmed/9308934>.

42. Detti B, Livi L, Scoccianti S, et al. Management of Stage II testicular seminoma over a period of 40 years. *Urol Oncol* 2009;27:534-538. Available at: <http://www.ncbi.nlm.nih.gov/pubmed/18848787>.

43. Choo R, Sandler H, Warde P, et al. Survey of radiation oncologists: practice patterns of the management of stage I seminoma of testis in Canada and a selected group in the United States. *Can J Urol* 2002;9:1479-1485. Available at: <http://www.ncbi.nlm.nih.gov/pubmed/12010592>.

44. Gospodarwicz MK, Sturgeon JF, Jewett MA. Early stage and advanced seminoma: role of radiation therapy, surgery, and chemotherapy. *Semin Oncol* 1998;25:160-173. Available at: <http://www.ncbi.nlm.nih.gov/pubmed/9562449>.

45. Domont J, Massard C, Patrikidou A, et al. A risk-adapted strategy of radiotherapy or cisplatin-based chemotherapy in stage II seminoma.



Urol Oncol 2011. Available at:

<http://www.ncbi.nlm.nih.gov/pubmed/21665493>.

46. Garcia-del-Muro X, Maroto P, Guma J, et al. Chemotherapy as an alternative to radiotherapy in the treatment of stage IIA and IIB testicular seminoma: a Spanish Germ Cell Cancer Group Study. J Clin Oncol 2008;26:5416-5421. Available at:

<http://www.ncbi.nlm.nih.gov/pubmed/18936476>.

47. de Wit R, Roberts JT, Wilkinson PM, et al. Equivalence of three or four cycles of bleomycin, etoposide, and cisplatin chemotherapy and of a 3- or 5-day schedule in good-prognosis germ cell cancer: a randomized study of the European Organization for Research and Treatment of Cancer Genitourinary Tract Cancer Cooperative Group and the Medical Research Council. J Clin Oncol 2001;19:1629-1640. Available at:

<http://www.ncbi.nlm.nih.gov/pubmed/11250991>.

48. Loehrer PJ, Sr., Johnson D, Elson P, et al. Importance of bleomycin in favorable-prognosis disseminated germ cell tumors: an Eastern Cooperative Oncology Group trial. J Clin Oncol 1995;13:470-476. Available at:

<http://www.ncbi.nlm.nih.gov/pubmed/7531223>.

49. Saxman SB, Finch D, Gonin R, Einhorn LH. Long-term follow-up of a phase III study of three versus four cycles of bleomycin, etoposide, and cisplatin in favorable-prognosis germ-cell tumors: the Indian University experience. J Clin Oncol 1998;16:702-706. Available at:

<http://www.ncbi.nlm.nih.gov/pubmed/9469360>.

50. Bajorin DF, Sarosdy MF, Pfister DG, et al. Randomized trial of etoposide and cisplatin versus etoposide and carboplatin in patients with good-risk germ cell tumors: a multiinstitutional study. J Clin Oncol 1993;11:598-606. Available at:

<http://www.ncbi.nlm.nih.gov/pubmed/8386751>.

51. Xiao H, Mazumdar M, Bajorin DF, et al. Long-term follow-up of patients with good-risk germ cell tumors treated with etoposide and cisplatin. J Clin Oncol 1997;15:2553-2558. Available at:

<http://www.ncbi.nlm.nih.gov/pubmed/9215824>.

52. Kondagunta GV, Bacik J, Bajorin D, et al. Etoposide and cisplatin chemotherapy for metastatic good-risk germ cell tumors. J Clin Oncol 2005;23:9290-9294. Available at:

<http://www.ncbi.nlm.nih.gov/pubmed/16361627>.

53. Tjan-Heijnen VC, Oosterhof GO, de Wit R, De Mulder PH. Treatment in germ cell tumours: state of the art. Eur J Surg Oncol 1997;23:110-117. Available at:

<http://www.ncbi.nlm.nih.gov/pubmed/9158183>.

54. de Wit R, Louwerens M, de Mulder PH, et al. Management of intermediate-prognosis germ-cell cancer: results of a phase I/II study of Taxol-BEP. Int J Cancer 1999;83:831-833. Available at:

<http://www.ncbi.nlm.nih.gov/pubmed/10597204>.

55. Becherer A, De Santis M, Karanikas G, et al. FDG PET is superior to CT in the prediction of viable tumour in post-chemotherapy seminoma residuals. Eur J Radiol 2005;54:284-288. Available at:

<http://www.ncbi.nlm.nih.gov/pubmed/15837411>.

56. Hinz S, Schrader M, Kempkensteffen C, et al. The role of positron emission tomography in the evaluation of residual masses after chemotherapy for advanced stage seminoma. J Urol 2008;179:936-940; discussion 940. Available at:

<http://www.ncbi.nlm.nih.gov/pubmed/18207171>.

57. Cremerius U, Wildberger JE, Borchers H, et al. Does positron emission tomography using 18-fluoro-2-deoxyglucose improve clinical staging of testicular cancer?--Results of a study in 50 patients. Urology 1999;54:900-904. Available at:

<http://www.ncbi.nlm.nih.gov/pubmed/10565755>.

58. Albers P, Bender H, Yilmaz H, et al. Positron emission tomography in the clinical staging of patients with Stage I and II testicular germ cell tumors. Urology 1999;53:808-811. Available at:

<http://www.ncbi.nlm.nih.gov/pubmed/10197862>.



59. Spermon JR, De Geus-Oei LF, Kiemeny LA, et al. The role of (18)fluoro-2-deoxyglucose positron emission tomography in initial staging and re-staging after chemotherapy for testicular germ cell tumours. *BJU Int* 2002;89:549-556. Available at: <http://www.ncbi.nlm.nih.gov/pubmed/11942962>.

60. De Santis M, Pont J. The role of positron emission tomography in germ cell cancer. *World J Urol* 2004;22:41-46. Available at: <http://www.ncbi.nlm.nih.gov/pubmed/15024601>.

61. De Santis M, Becherer A, Bokemeyer C, et al. 2-18fluoro-deoxy-D-glucose positron emission tomography is a reliable predictor for viable tumor in postchemotherapy seminoma: an update of the prospective multicentric SEMPET trial. *J Clin Oncol* 2004;22:1034-1039. Available at: <http://www.ncbi.nlm.nih.gov/pubmed/15020605>.

62. Ehrlich Y, Brames MJ, Beck SD, et al. Long-term follow-up of Cisplatin combination chemotherapy in patients with disseminated nonseminomatous germ cell tumors: is a postchemotherapy retroperitoneal lymph node dissection needed after complete remission? *J Clin Oncol* 2010;28:531-536. Available at: <http://www.ncbi.nlm.nih.gov/pubmed/20026808>.

63. Kollmannsberger C, Daneshmand S, So A, et al. Management of disseminated nonseminomatous germ cell tumors with risk-based chemotherapy followed by response-guided postchemotherapy surgery. *J Clin Oncol* 2010;28:537-542. Available at: <http://www.ncbi.nlm.nih.gov/pubmed/20026807>.

64. Kondagunta GV, Bacik J, Sheinfeld J, et al. Paclitaxel plus Ifosfamide followed by high-dose carboplatin plus etoposide in previously treated germ cell tumors. *J Clin Oncol* 2007;25:85-90. Available at: <http://www.ncbi.nlm.nih.gov/pubmed/17194908>.

65. Miller KD, Loehrer PJ, Gonin R, Einhorn LH. Salvage chemotherapy with vinblastine, ifosfamide, and cisplatin in recurrent seminoma. *J Clin Oncol* 1997;15:1427-1431. Available at: <http://www.ncbi.nlm.nih.gov/pubmed/9193335>.

66. Loehrer PJ, Sr., Lauer R, Roth BJ, et al. Salvage therapy in recurrent germ cell cancer: ifosfamide and cisplatin plus either vinblastine or etoposide. *Ann Intern Med* 1988;109:540-546. Available at: <http://www.ncbi.nlm.nih.gov/pubmed/2844110>.

67. Kondagunta GV, Bacik J, Donadio A, et al. Combination of paclitaxel, ifosfamide, and cisplatin is an effective second-line therapy for patients with relapsed testicular germ cell tumors. *J Clin Oncol* 2005;23:6549-6555. Available at: <http://www.ncbi.nlm.nih.gov/pubmed/16170162>.

68. Schmoll HJ, Jordan K, Huddart R, et al. Testicular seminoma: ESMO Clinical Practice Guidelines for diagnosis, treatment and follow-up. *Ann Oncol* 2010;21 Suppl 5:v140-146. Available at: <http://www.ncbi.nlm.nih.gov/pubmed/20555065>.

69. de Wit M, Brenner W, Hartmann M, et al. [18F]-FDG-PET in clinical stage I/II non-seminomatous germ cell tumours: results of the German multicentre trial. *Ann Oncol* 2008;19:1619-1623. Available at: <http://www.ncbi.nlm.nih.gov/pubmed/18453520>.

70. Huddart RA, O'Doherty MJ, Padhani A, et al. 18fluorodeoxyglucose positron emission tomography in the prediction of relapse in patients with high-risk, clinical stage I nonseminomatous germ cell tumors: preliminary report of MRC Trial TE22--the NCRI Testis Tumour Clinical Study Group. *J Clin Oncol* 2007;25:3090-3095. Available at: <http://www.ncbi.nlm.nih.gov/pubmed/17634488>.

71. Sheinfeld J, Herr HW. Role of surgery in management of germ cell tumor. *Semin Oncol* 1998;25:203-209. Available at: <http://www.ncbi.nlm.nih.gov/pubmed/9562453>.

72. Colls BM, Harvey VJ, Skelton L, et al. Late results of surveillance of clinical stage I nonseminoma germ cell testicular tumours: 17 years' experience in a national study in New Zealand. *BJU Int* 1999;83:76-82. Available at: <http://www.ncbi.nlm.nih.gov/pubmed/10233456>.



73. Read G, Stenning SP, Cullen MH, et al. Medical Research Council prospective study of surveillance for stage I testicular teratoma. Medical Research Council Testicular Tumors Working Party. *J Clin Oncol* 1992;10:1762-1768. Available at: <http://www.ncbi.nlm.nih.gov/pubmed/1403057>.
74. Kakiashvili D, Anson-Cartwright L, Sturgeon JF, Warde PR, Chung P, Moore M, Wang L, Azuero J, Jewett MA. Non risk-adapted surveillance management for clinical stage I nonseminomatous testis tumors [abstract]. *J Urol* 2007;177:278 (Abstract 835). Available at:
75. Zuniga A, Kakiashvili D, Jewett MA. Surveillance in stage I nonseminomatous germ cell tumours of the testis. *BJU Int* 2009;104:1351-1356. Available at: <http://www.ncbi.nlm.nih.gov/pubmed/19840012>.
76. Oliver RT, Ong J, Shamash J, et al. Long-term follow-up of Anglian Germ Cell Cancer Group surveillance versus patients with Stage 1 nonseminoma treated with adjuvant chemotherapy. *Urology* 2004;63:556-561. Available at: <http://www.ncbi.nlm.nih.gov/pubmed/15028457>.
77. de Bruin MJ, Oosterhof GO, Debruyne FM. Nerve-sparing retroperitoneal lymphadenectomy for low stage testicular cancer. *Br J Urol* 1993;71:336-339. Available at: <http://www.ncbi.nlm.nih.gov/pubmed/8386581>.
78. Stephenson AJ, Bosl GJ, Motzer RJ, et al. Retroperitoneal lymph node dissection for nonseminomatous germ cell testicular cancer: impact of patient selection factors on outcome. *J Clin Oncol* 2005;23:2781-2788. Available at: <http://www.ncbi.nlm.nih.gov/pubmed/15837993>.
79. Bohlen D, Borner M, Sonntag RW, et al. Long-term results following adjuvant chemotherapy in patients with clinical stage I testicular nonseminomatous malignant germ cell tumors with high risk factors. *J Urol* 1999;161:1148-1152. Available at: <http://www.ncbi.nlm.nih.gov/pubmed/10081858>.
80. Bohlen D, Burkhard FC, Mills R, et al. Fertility and sexual function following orchiectomy and 2 cycles of chemotherapy for stage I high risk nonseminomatous germ cell cancer. *J Urol* 2001;165:441-444. Available at: <http://www.ncbi.nlm.nih.gov/pubmed/11176393>.
81. Chevreau C, Mazerolles C, Soulie M, et al. Long-term efficacy of two cycles of BEP regimen in high-risk stage I nonseminomatous testicular germ cell tumors with embryonal carcinoma and/or vascular invasion. *Eur Urol* 2004;46:209-214. Available at: <http://www.ncbi.nlm.nih.gov/pubmed/15245815>.
82. Cullen MH, Stenning SP, Parkinson MC, et al. Short-course adjuvant chemotherapy in high-risk stage I nonseminomatous germ cell tumors of the testis: a Medical Research Council report. *J Clin Oncol* 1996;14:1106-1113. Available at: <http://www.ncbi.nlm.nih.gov/pubmed/8648364>.
83. Oliver RT, Raja MA, Ong J, Gallagher CJ. Pilot study to evaluate impact of a policy of adjuvant chemotherapy for high risk stage 1 malignant teratoma on overall relapse rate of stage 1 cancer patients. *J Urol* 1992;148:1453-1455. Available at: <http://www.ncbi.nlm.nih.gov/pubmed/1279211>.
84. Pont J, Albrecht W, Postner G, et al. Adjuvant chemotherapy for high-risk clinical stage I nonseminomatous testicular germ cell cancer: long-term results of a prospective trial. *J Clin Oncol* 1996;14:441-448. Available at: <http://www.ncbi.nlm.nih.gov/pubmed/8636755>.
85. Studer UE, Fey MF, Calderoni A, et al. Adjuvant chemotherapy after orchiectomy in high-risk patients with clinical stage I non-seminomatous testicular cancer. *Eur Urol* 1993;23:444-449. Available at: <http://www.ncbi.nlm.nih.gov/pubmed/7687549>.
86. Sharir S, Foster RS, Donohue JP, Jewett MA. What is the appropriate follow-up after treatment? *Semin Urol Oncol* 1996;14:45-53. Available at: <http://www.ncbi.nlm.nih.gov/pubmed/8833389>.



87. Studer UE, Fey MF, Calderoni A, et al. Adjuvant chemotherapy after orchiectomy in high-risk patients with clinical stage I non-seminomatous testicular cancer. *Eur Urol* 1993;23:444-449. Available at: <http://www.ncbi.nlm.nih.gov/pubmed/7687549>.

88. Bohlen D, Borner M, Sonntag RW, et al. Long-term results following adjuvant chemotherapy in patients with clinical stage I testicular nonseminomatous malignant germ cell tumors with high risk factors. *J Urol* 1999;161:1148-1152. Available at: <http://www.ncbi.nlm.nih.gov/pubmed/10081858>.

89. Pont J, Albrecht W, Postner G, et al. Adjuvant chemotherapy for high-risk clinical stage I nonseminomatous testicular germ cell cancer: long-term results of a prospective trial. *J Clin Oncol* 1996;14:441-448. Available at: <http://www.ncbi.nlm.nih.gov/pubmed/8636755>.

90. Chevreau C, Mazerolles C, Soulie M, et al. Long-term efficacy of two cycles of BEP regimen in high-risk stage I nonseminomatous testicular germ cell tumors with embryonal carcinoma and/or vascular invasion. *Eur Urol* 2004;46:209-214; discussion 214-205. Available at: <http://www.ncbi.nlm.nih.gov/pubmed/15245815>.

91. Meinardi MT, Gietema JA, van der Graaf WT, et al. Cardiovascular morbidity in long-term survivors of metastatic testicular cancer. *J Clin Oncol* 2000;18:1725-1732. Available at: <http://www.ncbi.nlm.nih.gov/pubmed/10764433>.

92. Berger CC, Bokemeyer C, Schneider M, et al. Secondary Raynaud's phenomenon and other late vascular complications following chemotherapy for testicular cancer. *Eur J Cancer* 1995;31A:2229-2238. Available at: <http://www.ncbi.nlm.nih.gov/pubmed/8652248>.

93. Strumberg D, Brugge S, Korn MW, et al. Evaluation of long-term toxicity in patients after cisplatin-based chemotherapy for non-seminomatous testicular cancer. *Ann Oncol* 2002;13:229-236. Available at: <http://www.ncbi.nlm.nih.gov/pubmed/11885999>.

94. Bokemeyer C, Berger CC, Kuczyk MA, Schmoll HJ. Evaluation of long-term toxicity after chemotherapy for testicular cancer. *J Clin Oncol* 1996;14:2923-2932. Available at: <http://www.ncbi.nlm.nih.gov/pubmed/8918489>.

95. Huddart RA, Norman A, Shahidi M, et al. Cardiovascular disease as a long-term complication of treatment for testicular cancer. *J Clin Oncol* 2003;21:1513-1523. Available at: <http://www.ncbi.nlm.nih.gov/pubmed/12697875>.

96. Bajorin DF, Motzer RJ, Rodriguez E, et al. Acute nonlymphocytic leukemia in germ cell tumor patients treated with etoposide-containing chemotherapy. *J Natl Cancer Inst* 1993;85:60-62. Available at: <http://www.ncbi.nlm.nih.gov/pubmed/7677936>.

97. Albers P, Siener R, Kregge S, et al. Randomized Phase III Trial Comparing Retroperitoneal Lymph Node Dissection With One Course of Bleomycin and Etoposide Plus Cisplatin Chemotherapy in the Adjuvant Treatment of Clinical Stage I Nonseminomatous Testicular Germ Cell Tumors: AUO Trial AH 01/94 by the German Testicular Cancer Study Group. *J Clin Oncol* 2008;26:2966-2972. Available at: <http://jco.ascopubs.org/cgi/content/abstract/26/18/2966>.

98. Culine S, Theodore C, Terrier-Lacombe MJ, Droz JP. Primary chemotherapy in patients with nonseminomatous germ cell tumors of the testis and biological disease only after orchiectomy. *J Urol* 1996;155:1296-1298. Available at: <http://www.ncbi.nlm.nih.gov/pubmed/8632558>.

99. Davis BE, Herr HW, Fair WR, Bosl GJ. The management of patients with nonseminomatous germ cell tumors of the testis with serologic disease only after orchiectomy. *J Urol* 1994;152:111-113; discussion 114. Available at: <http://www.ncbi.nlm.nih.gov/pubmed/7515445>.

100. Stephenson AJ, Bosl GJ, Motzer RJ, et al. Nonrandomized comparison of primary chemotherapy and retroperitoneal lymph node dissection for clinical stage IIA and IIB nonseminomatous germ cell





testicular cancer. *J Clin Oncol* 2007;25:5597-5602. Available at: <http://www.ncbi.nlm.nih.gov/pubmed/18065732>.

101. Weissbach L, Bussar-Maatz R, Flechtner H, et al. RPLND or primary chemotherapy in clinical stage IIA/B nonseminomatous germ cell tumors? Results of a prospective multicenter trial including quality of life assessment. *Eur Urol* 2000;37:582-594. Available at: <http://www.ncbi.nlm.nih.gov/pubmed/10765098>.

102. Donohue JP, Thornhill JA, Foster RS, et al. Clinical stage B non-seminomatous germ cell testis cancer: the Indiana University experience (1965-1989) using routine primary retroperitoneal lymph node dissection. *Eur J Cancer* 1995;31A:1599-1604. Available at: <http://www.ncbi.nlm.nih.gov/pubmed/7488408>.

103. Pizzocaro G. Retroperitoneal lymph node dissection in clinical stage IIA and IIB nonseminomatous germ cell tumours of the testis. *Int J Androl* 1987;10:269-275. Available at: <http://www.ncbi.nlm.nih.gov/pubmed/3034796>.

104. Culine S, Theodore C, Court BH, et al. Evaluation of primary standard cisplatin-based chemotherapy for clinical stage II non-seminomatous germ cell tumours of the testis. *Br J Urol* 1997;79:258-262. Available at: <http://www.ncbi.nlm.nih.gov/pubmed/9052479>.

105. Rabbani F, Sheinfeld J, Farivar-Mohseni H, et al. Low-volume nodal metastases detected at retroperitoneal lymphadenectomy for testicular cancer: pattern and prognostic factors for relapse. *J Clin Oncol* 2001;19:2020-2025. Available at: <http://www.ncbi.nlm.nih.gov/pubmed/11283135>.

106. Stephenson AJ, Bosl GJ, Bajorin DF, et al. Retroperitoneal lymph node dissection in patients with low stage testicular cancer with embryonal carcinoma predominance and/or lymphovascular invasion. *J Urol* 2005;174:557-560; discussion 560. Available at: <http://www.ncbi.nlm.nih.gov/pubmed/16006891>.

107. Carver BS, Shayegan B, Eggener S, et al. Incidence of metastatic nonseminomatous germ cell tumor outside the boundaries of a modified postchemotherapy retroperitoneal lymph node dissection. *J Clin Oncol* 2007;25:4365-4369. Available at: <http://www.ncbi.nlm.nih.gov/pubmed/17906201>.

108. Williams SD, Stablein DM, Einhorn LH, et al. Immediate adjuvant chemotherapy versus observation with treatment at relapse in pathological stage II testicular cancer. *N Engl J Med* 1987;317:1433-1438. Available at: <http://www.ncbi.nlm.nih.gov/pubmed/2446132>.

109. Sheinfeld J, Motzer RJ, Rabbani F, et al. Incidence and clinical outcome of patients with teratoma in the retroperitoneum following primary retroperitoneal lymph node dissection for clinical stages I and IIA nonseminomatous germ cell tumors. *J Urol* 2003;170:1159-1162. Available at: <http://www.ncbi.nlm.nih.gov/pubmed/14501715>.

110. Vogelzang NJ, Fraley EE, Lange PH, et al. Stage II nonseminomatous testicular cancer: a 10-year experience. *J Clin Oncol* 1983;1:171-178. Available at: <http://www.ncbi.nlm.nih.gov/pubmed/6668498>.

111. Behnia M, Foster R, Einhorn LH, et al. Adjuvant bleomycin, etoposide and cisplatin in pathological stage II non-seminomatous testicular cancer. the Indiana University experience. *Eur J Cancer* 2000;36:472-475. Available at: <http://www.ncbi.nlm.nih.gov/pubmed/10717522>.

112. Kondagunta GV, Sheinfeld J, Mazumdar M, et al. Relapse-free and overall survival in patients with pathologic stage II nonseminomatous germ cell cancer treated with etoposide and cisplatin adjuvant chemotherapy. *J Clin Oncol* 2004;22:464-467. Available at: <http://www.ncbi.nlm.nih.gov/pubmed/14752068>.

113. Motzer RJ, Sheinfeld J, Mazumdar M, et al. Etoposide and cisplatin adjuvant therapy for patients with pathologic stage II germ cell tumors. *J Clin Oncol* 1995;13:2700-2704. Available at: <http://www.ncbi.nlm.nih.gov/pubmed/7595727>.

114. Donohue JP, Thornhill JA, Foster RS, et al. The role of retroperitoneal lymphadenectomy in clinical stage B testis cancer: the Indiana University experience (1965 to 1989). *J Urol* 1995;153:85-89. Available at: <http://www.ncbi.nlm.nih.gov/pubmed/7966799>.

115. Hartlapp JH, Weissbach L, Bussar-Maatz R. Adjuvant chemotherapy in nonseminomatous testicular tumour stage II. *Int J Androl* 1987;10:277-284. Available at: <http://www.ncbi.nlm.nih.gov/pubmed/2438221>.

116. Horwich A, Norman A, Fisher C, et al. Primary chemotherapy for stage II nonseminomatous germ cell tumors of the testis. *J Urol* 1994;151:72-77. Available at: <http://www.ncbi.nlm.nih.gov/pubmed/8254836>.

117. Logothetis CJ, Swanson DA, Dexeus F, et al. Primary chemotherapy for clinical stage II nonseminomatous germ cell tumors of the testis: a follow-up of 50 patients. *J Clin Oncol* 1987;5:906-911. Available at: <http://www.ncbi.nlm.nih.gov/pubmed/2438389>.

118. Sternberg CN. Role of primary chemotherapy in stage I and low-volume stage II nonseminomatous germ-cell testis tumors. *Urol Clin North Am* 1993;20:93-9109. Available at: <http://www.ncbi.nlm.nih.gov/pubmed/8382000>.

119. Bosl GJ, Geller NL, Bajorin D, et al. A randomized trial of etoposide + cisplatin versus vinblastine + bleomycin + cisplatin + cyclophosphamide + dactinomycin in patients with good-prognosis germ cell tumors. *J Clin Oncol* 1988;6:1231-1238. Available at: <http://www.ncbi.nlm.nih.gov/pubmed/2457657>.

120. Williams SD, Birch R, Einhorn LH, et al. Treatment of disseminated germ-cell tumors with cisplatin, bleomycin, and either vinblastine or etoposide. *N Engl J Med* 1987;316:1435-1440. Available at: <http://www.ncbi.nlm.nih.gov/pubmed/2437455>.

121. Einhorn LH, Williams SD, Loehrer PJ, et al. Evaluation of optimal duration of chemotherapy in favorable-prognosis disseminated germ

cell tumors: a Southeastern Cancer Study Group protocol. *J Clin Oncol* 1989;7:387-391. Available at: <http://www.ncbi.nlm.nih.gov/pubmed/2465391>.

122. de Wit R, Stoter G, Kaye SB, et al. Importance of bleomycin in combination chemotherapy for good-prognosis testicular nonseminoma: a randomized study of the European Organization for Research and Treatment of Cancer Genitourinary Tract Cancer Cooperative Group. *J Clin Oncol* 1997;15:1837-1843. Available at: <http://www.ncbi.nlm.nih.gov/pubmed/9164193>.

123. Horwich A, Sleijfer DT, Fossa SD, et al. Randomized trial of bleomycin, etoposide, and cisplatin compared with bleomycin, etoposide, and carboplatin in good-prognosis metastatic nonseminomatous germ cell cancer: a Multiinstitutional Medical Research Council/European Organization for Research and Treatment of Cancer Trial. *J Clin Oncol* 1997;15:1844-1852. Available at: <http://www.ncbi.nlm.nih.gov/pubmed/9164194>.

124. Jones RH, Vasey PA. Part II: testicular cancer--management of advanced disease. *Lancet Oncol* 2003;4:738-747. Available at: <http://www.ncbi.nlm.nih.gov/pubmed/14662430>.

125. de Wit R, Stoter G, Sleijfer DT, et al. Four cycles of BEP vs four cycles of VIP in patients with intermediate-prognosis metastatic testicular non-seminoma: a randomized study of the EORTC Genitourinary Tract Cancer Cooperative Group. *European Organization for Research and Treatment of Cancer. Br J Cancer* 1998;78:828-832. Available at: <http://www.ncbi.nlm.nih.gov/pubmed/9743309>.

126. Frohlich MW, Small EJ. Stage II nonseminomatous testis cancer: the roles of primary and adjuvant chemotherapy. *Urol Clin North Am* 1998;25:451-459. Available at: <http://www.ncbi.nlm.nih.gov/pubmed/9728214>.

127. Nichols CR, Catalano PJ, Crawford ED, et al. Randomized comparison of cisplatin and etoposide and either bleomycin or ifosfamide in treatment of advanced disseminated germ cell tumors: an



Eastern Cooperative Oncology Group, Southwest Oncology Group, and Cancer and Leukemia Group B Study. J Clin Oncol 1998;16:1287-1293. Available at: <http://www.ncbi.nlm.nih.gov/pubmed/9552027>.

128. Toner GC, Panicek DM, Heelan RT, et al. Adjunctive surgery after chemotherapy for nonseminomatous germ cell tumors: recommendations for patient selection. J Clin Oncol 1990;8:1683-1694. Available at: <http://www.ncbi.nlm.nih.gov/pubmed/2170590>.

129. Kuczyk M, Machtens S, Stief C, Jonas U. Management of the post-chemotherapy residual mass in patients with advanced stage non-seminomatous germ cell tumors (NSGCT). Int J Cancer 1999;83:852-855. Available at: <http://www.ncbi.nlm.nih.gov/pubmed/10597210>.

130. Hartmann JT, Schmoll HJ, Kuczyk MA, et al. Postchemotherapy resections of residual masses from metastatic non-seminomatous testicular germ cell tumors. Ann Oncol 1997;8:531-538. Available at: <http://www.ncbi.nlm.nih.gov/pubmed/9261521>.

131. Motzer RJ, Geller NL, Tan CC, et al. Salvage chemotherapy for patients with germ cell tumors. The Memorial Sloan-Kettering Cancer Center experience (1979-1989). Cancer 1991;67:1305-1310. Available at: <http://www.ncbi.nlm.nih.gov/pubmed/1703917>.

132. Einhorn LH, Williams SD, Chamness A, et al. High-dose chemotherapy and stem-cell rescue for metastatic germ-cell tumors. N Engl J Med 2007;357:340-348. Available at: <http://www.ncbi.nlm.nih.gov/pubmed/17652649>.

133. Lorch A, Beyer J, Bascoul-Mollevi C, et al. Prognostic factors in patients with metastatic germ cell tumors who experienced treatment failure with cisplatin-based first-line chemotherapy. J Clin Oncol 2010;28:4906-4911. Available at: <http://www.ncbi.nlm.nih.gov/pubmed/20956623>.

134. Loehrer PJ, Sr., Gonin R, Nichols CR, et al. Vinblastine plus ifosfamide plus cisplatin as initial salvage therapy in recurrent germ cell

tumor. J Clin Oncol 1998;16:2500-2504. Available at: <http://www.ncbi.nlm.nih.gov/pubmed/9667270>.

135. Lorch A, Rick O, Wundisch T, et al. High dose chemotherapy as salvage treatment for unresectable late relapse germ cell tumors. J Urol 2010;184:168-173. Available at: <http://www.ncbi.nlm.nih.gov/pubmed/20483152>.

136. Lorch A, Neubauer A, Hackenthal M, et al. High-dose chemotherapy (HDCT) as second-salvage treatment in patients with multiple relapsed or refractory germ-cell tumors. Ann Oncol 2010;21:820-825. Available at: <http://www.ncbi.nlm.nih.gov/pubmed/19822531>.

137. Motzer RJ, Bosl GJ. High-dose chemotherapy for resistant germ cell tumors: recent advances and future directions. J Natl Cancer Inst 1992;84:1703-1709. Available at: <http://www.ncbi.nlm.nih.gov/pubmed/1331482>.

138. Feldman DR, Sheinfeld J, Bajorin DF, et al. TI-CE high-dose chemotherapy for patients with previously treated germ cell tumors: results and prognostic factor analysis. J Clin Oncol 2010;28:1706-1713. Available at: <http://www.ncbi.nlm.nih.gov/pubmed/20194867>.

139. Wood DP, Jr., Herr HW, Motzer RJ, et al. Surgical resection of solitary metastases after chemotherapy in patients with nonseminomatous germ cell tumors and elevated serum tumor markers. Cancer 1992;70:2354-2357. Available at: <http://www.ncbi.nlm.nih.gov/pubmed/1382832>.

140. De Giorgi U, Rosti G, Aieta M, et al. Phase II study of oxaliplatin and gemcitabine salvage chemotherapy in patients with cisplatin-refractory nonseminomatous germ cell tumor. Eur Urol 2006;50:1032-1038; discussion 1038-1039. Available at: <http://www.ncbi.nlm.nih.gov/pubmed/16757095>.

141. Kollmannsberger C, Beyer J, Liersch R, et al. Combination chemotherapy with gemcitabine plus oxaliplatin in patients with



intensively pretreated or refractory germ cell cancer: a study of the German Testicular Cancer Study Group. *J Clin Oncol* 2004;22:108-114. Available at: <http://www.ncbi.nlm.nih.gov/pubmed/14701772>.

142. Pectasides D, Pectasides M, Farmakis D, et al. Gemcitabine and oxaliplatin (GEMOX) in patients with cisplatin-refractory germ cell tumors: a phase II study. *Ann Oncol* 2004;15:493-497. Available at: <http://www.ncbi.nlm.nih.gov/pubmed/14998855>.

143. Bokemeyer C, Oechsle K, Honecker F, et al. Combination chemotherapy with gemcitabine, oxaliplatin, and paclitaxel in patients with cisplatin-refractory or multiply relapsed germ-cell tumors: a study of the German Testicular Cancer Study Group. *Ann Oncol* 2008;19:448-453. Available at: <http://www.ncbi.nlm.nih.gov/pubmed/18006893>.

144. Einhorn LH, Brames MJ, Juliar B, Williams SD. Phase II study of paclitaxel plus gemcitabine salvage chemotherapy for germ cell tumors after progression following high-dose chemotherapy with tandem transplant. *J Clin Oncol* 2007;25:513-516. Available at: <http://www.ncbi.nlm.nih.gov/pubmed/17290059>.

145. Mulherin BP, Brames MJ, Einhorn LH. Long-term survival with paclitaxel and gemcitabine for germ cell tumors after progression following high-dose chemotherapy with tandem transplants [abstract]. *J Clin Oncol* 2011;29:Abstract 4562. Available at: [http://meeting.ascopubs.org/cgi/content/abstract/29/15\\_suppl/4562](http://meeting.ascopubs.org/cgi/content/abstract/29/15_suppl/4562).

146. Fossa SD, Bokemeyer C, Gerl A, et al. Treatment outcome of patients with brain metastases from malignant germ cell tumors. *Cancer* 1999;85:988-997. Available at: <http://www.ncbi.nlm.nih.gov/pubmed/10091779>.

147. Bokemeyer C, Nowak P, Haupt A, et al. Treatment of brain metastases in patients with testicular cancer. *J Clin Oncol* 1997;15:1449-1454. Available at: <http://www.ncbi.nlm.nih.gov/pubmed/9193339>.

148. Hartmann J, Bamberg M, Albers P, et al. Multidisciplinary treatment and prognosis of patients with central nervous metastases (CNS) from testicular germ cell tumour (GCT) origin [abstract] *Proc Ann Soc Clin Oncol* 2003;22:400:Abstract 1607.